

Case 20

A 27-year-old Thai female from Bangkok

Chief complaint: Progressive diffuse hair loss for 3 months

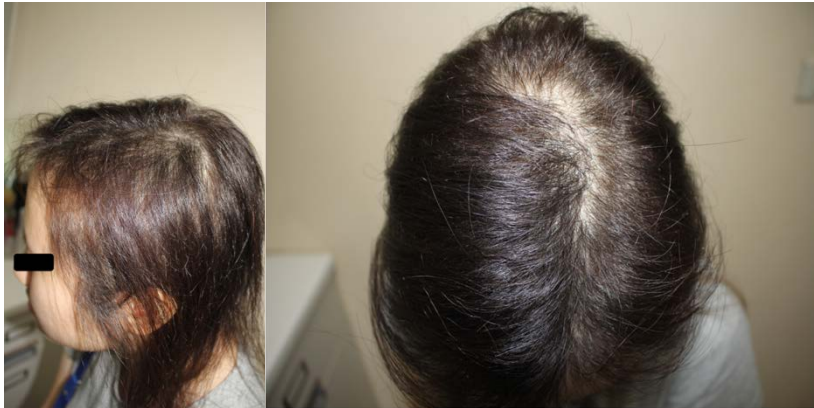

Fig. 20.1

Present illness:

3 months ago, she had gradually developed asymptomatic diffuse scalp hair loss. She had neither systemic symptoms nor chronic illness. She denied hot-comb straightening, bleaching or permanent waving. She has regular menstrual cycle but also has hypermenorrhea with using tampons more than 10 pads per day during her period.

Past history: None

Physical examination:

- HEENT: Moderately pale conjunctivae, no jaundice
- Others: Unremarkable

Dermatological examination: (Fig. 20.1)

- Diffuse non-scarring alopecia

- Sparse, fragile, and thin hairs over scalp, especially on vertex and temporal area
- Hair pull test: Positive
- Hair tug test: Positive
- Nails are normal
- No other skin lesions

Trichoscopy: (Fig. 20.2)

- Short regrowing hairs (a)
- Discrete spotty glistening white areas on the scalp
- Cuticle with separation, node-like swelling (b)
- No exclamation mark hair




Fig 20.2

Microscopy: (Fig. 20.3)

- Splayed paint brush or fan-like array of hair shafts

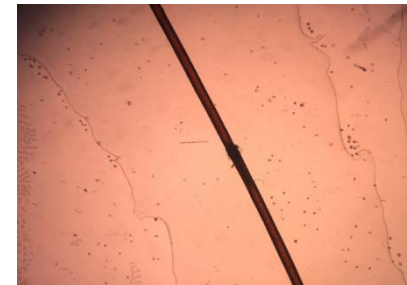


Fig. 20.3

Investigation:

- CBC: Hb 7 g/dL, Hct 24.5 %, MCV 59 fl, Plt 550,000/ mm³, WBC 7,020/mm³ (N 79%, L 12%, M 8%, E 1%) RDW 21% with aniso-poikilocytosis with hypochromic-microcytic anemia
- Hb typing A2A
- Serum iron 8 ug/dL (35-150)
- TIBC 465 ug/dL (250-450)
- Ferritin < 1.00 ng/mL (4.63-204)
- Free T3 2.71 (1.88-3.18), Free T4 1.01 (0.70-1.48), TSH 1.626 (0.35-4.94)
- ANA: negative

Gynecological examination: abnormal uterine bleeding suspected non-structural cause from endometrium

Diagnosis: Telogen effluvium, trichorrhexis nodosa, and iron deficiency anemia

Treatment:

- Ferrous fumarate (200) 1 tab po tid pc
- Folic acid 1 tab po od
- Transamine (250) 2 tab po tid pc

Presenter: Teerapong Rattananukrom, MD

Consultant: Poonkiat Suchonwanit, MD

Discussion:

Telogen effluvium (TE) was first described by Kligman in 1961. It is a common cause of diffuse non-scarring hair loss. TE occurs within 3 months after aggravating factors and is usually self-limited within 6 months. The hair loss is usually less than 50% of the scalp hair.¹ The hair pull test is strongly positive in early TE cases, indicating a process of active hair shedding.²

The trichogram (hair pluck test) shows greater than 25% of telogen hair.³ Tricoscopy in TE demonstrates empty follicles and numerous short regrowing hairs.

The mechanism of TE is premature termination of anagen hairs induced by several factors such as physiologic stress, drugs, chronic illness, thyroid diseases, malnutrition, and iron deficiency anemia (IDA). This would lead anagen hairs to enter catagen and telogen phase.⁵ Telogen effluvium consists of five functional types which were revealed by Headington et al.⁶:

Taking history and clinical examination are important to define the cause of TE. Furthermore, blood testing includes complete blood count, serum ferritin and T3, T4, thyroid stimulating hormone (TSH) should be investigated in the suspected cases.⁸ Antinuclear antibody titer and serum zinc level should be done if there are other features on history or on examination to suggest these conditions.⁸ IDA is one of the most important causes associated with TE. Risk factors for IDA include heavy menstrual blood loss (>80 mL per month, affecting approximately 10% of women), use of an intrauterine device, history of IDA, and insufficient iron intake.⁹

Iron is a cofactor in DNA synthesis of matrix cells. Follicular matrix cells are among the most rapidly dividing cells and are sensitive to diminish in iron storage. Profound IDA can induce telogen follicles fail to reenter anagen and reduce the proliferation of matrix cells.⁶ The arrest of matrix proliferation can cause TE. A cross-sectional study by Rushton et al.¹⁰ of 200 female patients with CTE showed that 65% had serum ferritin concentrations less than 40 ng/mL and that 95% had serum ferritin concentrations less than 70 ng/mL.

Interestingly, it was noted that 40 ng/mL is the lower limit of normal for males and that 70 ng/mL is the upper 99% confidence limit for iron staining in the bone marrow, an indication of being iron replete.

Trichorrhexis nodosa (TN) is a common acquired hair shaft disorder which increases fragility of the hair shaft, resulting in hair breakage. TN can be acquired or congenital, and its distribution can be localized or generalized.¹¹ On physical examination, a short segment of hair shaft splits longitudinally into numerous small fibers in one or more areas. The outer fibers bulge out and cause a segmental increase in hair diameter. Macroscopically these segments may reassemble nodules located along the hair shaft. Hairs eventually break at these points leaving brush-like ends. On trichoscopy (without immersion fluid), whitish contours of the splitting fibers may be visible. At high magnifications, trichoscopy shows the numerous small fibers that produce a picture resembling two brooms or brushes aligned in opposition.

Acquired TN is a consequence of chemical or physical trauma such as dyes, thermal hair irons, hairdryers, excessive washing and manipulation. Moreover, TN has also been related to iron deficiency. Iron deficiency causes lusterless and brittle hair, dryness, and focal narrowing or splitting of the hair shaft, which have been attributed to impaired keratin production.¹² In the 22 cases of acquired TN reported in Japan from 1942–2007, iron deficiency was reported in two cases which likewise improved with iron supplementation.¹³ In order to reverse hair loss, some authors suggest that serum ferritin level should be maintained above 40ng/dl¹⁴ or 70ng/dl.¹⁵ Adequate dietary intake and oral administration of iron supplement are effective

therapy. Iron should be given for 3-6 months till stores are replenished.

In conclusion, we present a female case with TE and TN caused by IDA. Her hair problems were improved after receiving adequate iron supplement. TE is a common cause of diffuse non-scarring alopecia, whereas TN is the commonest hair shaft defect. IDA is one of the common causes in both conditions. The condition interrupts hair matrix proliferation in TE and also impairs keratin production in TN. Hair restoration usually occurs after iron supplement adequately.

References:

1. Trueb RM. Diffuse hair loss. In: Blume-Peytavi U, Tosti A, Whiting DA, Trueb R, editors. Hair growth and disorders, 1st edn. Berlin: Springer; 2008. pp.259-272.
2. Piérard GE, Piérard-Franchimont C, Marks R, Elsner P, for the EEMCO group (European Expert Group on Efficacy Measurement of Cosmetics and Other Topical Products). EEMCO guidance for the assessment of hair shedding and alopecia. *Skin Pharmacol Physiol* 2004;17:98-110.
3. Sinclair R. Diffuse hair loss. *Int J Dermatol*. 1999;38:1-18.
4. Khunkhet S, Vachiramon V, Suchonwanit P. Trichoscopic clues for diagnosis of alopecia areata and trichotillomania in Asians. *Int J Dermatol*. 2017;56:161-165.
5. Messenger AG, Berker DA, Sinclair RD. Disorders of hair. In: Burns T, Breathnach S, Cox N, Griffiths C, editors. Rook's text book of dermatology, 8th edn. Oxford: Blackwell Publishing; 2010. pp. 66.1- 66.100.
6. Headington JT. Telogen effluvium. New concepts and review. *Arch Dermatol* 1993;129:356-63.
7. Gilmore S, Sinclair R. Chronic telogen effluvium is due to a reduction in the variance of anagen duration. *Australas J Dermatol* 2010;51:163-7.
8. Jain VK, Kataria U, Dayal S. Study of diffuse alopecia in females. *Indian J Dermatol Venereol Leprol*. 2000;66:65-68.
9. Centers for Disease Control (CDC). Recommendations to prevent and control iron deficiency in the United States. *Morb Mortal Wkly Rep* 1998;47:1-36.
10. Rushton DH, Norris MJ, Dover R, Busuttill N. Causes of hair loss and the developments in hair rejuvenation. *Int J Cosmet Sci* 2002;24:17-23.
11. Smith RA, Ross JS, Bunker CB. Localized trichorrhexis nodosa. *Clin Exp Dermatol* 1994;19:441-2.
12. Syozo S. *Semin Dermatol* 1991; 10: 313-319.
13. Miyamoto M, Tsuboi R, Oh-I T. Case of acquired trichorrhexis nodosa: scanning electron microscopic observation. *J Dermatol*. 2009;36:109-10.
14. Kantor J, Kessler LJ, Brooks DG, Cotsarelis G. Decreased serum ferritin is associated with alopecia in women. *J Invest Dermatol*. 2003;121:985-8.
15. Trost LB, Bergfeld WF, Calogeras E. The diagnosis and treatment of iron deficiency and its potential relationship to hair loss. *J Am Acad Dermatol*. 2006;54:824-44.