

Case 16

A 30 year-old Thai female from Bangkok.

Chief complaint: Indurated plaques with reddish-brown papules on extremities for 5 months

Present illness:

5 months previously, she noticed slow progressive asymptomatic subcutaneous rash with scattered reddish-brown papules on both legs and right arm. She denied fever, weight loss, arthralgia, and other systemic symptoms.

Past history:

No previous significant underlying disease.

No history of contact TB patient.

Current medication: oral contraceptive pill.

Physical examination:

V/S: T 37.2°C, PR 70/min, RR 16/min, BP 100/60 mmHg

HEENT: not pale, anicteric sclerae

Lymph node: no lymphadenopathy

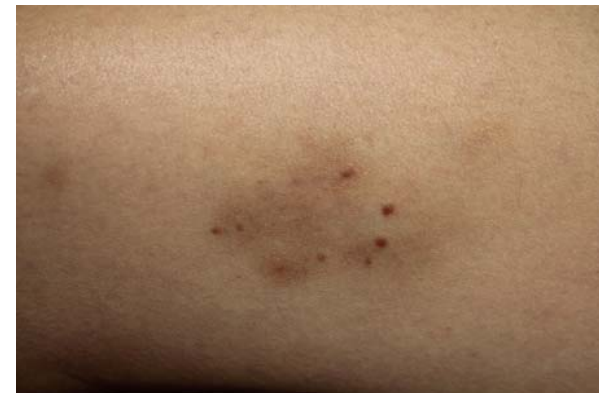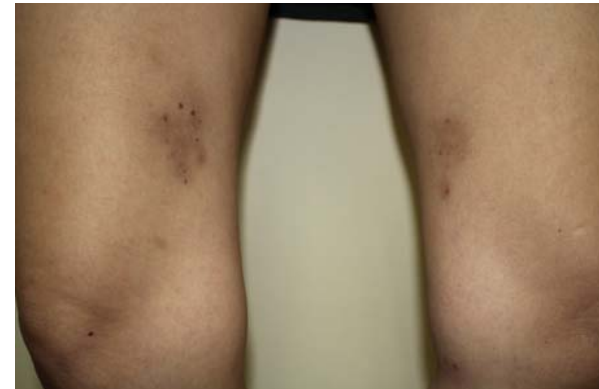CVS: normal s1s2, no murmur

RS: normal chest contour, normal breath sound

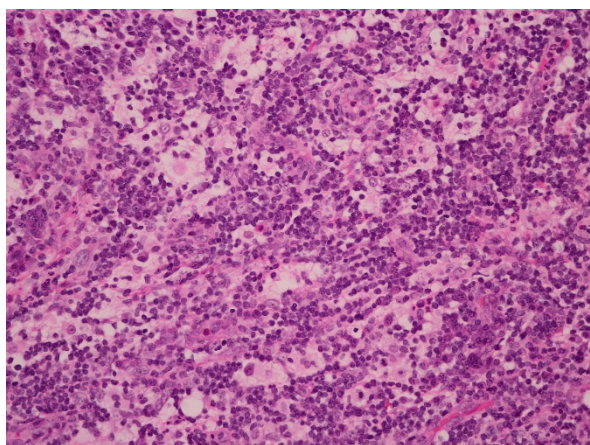
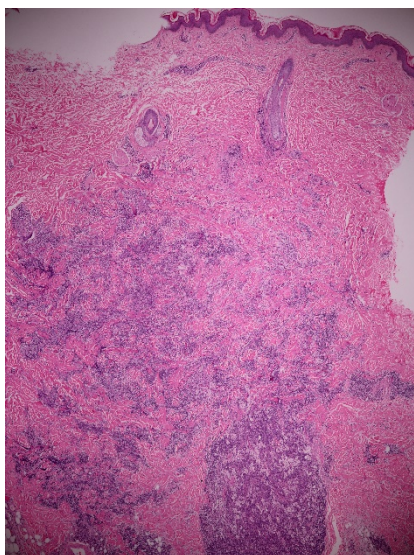
Abdomen: soft, no hepatosplenomegaly

Skin examination:

- Multiple brownish indurated plaques overlying with discrete reddish-brown papules on right arm, both inner thighs and legs.



Histopathology: (S16-8268A, right arm)



- Dense nodular and diffuse inflammatory-cell infiltrate of giant epithelioid histiocytes, with abundant pale eosinophilic

cytoplasm and vesicular nuclei admixed with numerous lymphocytes, some plasma cells and a few eosinophils, in the deep dermis and subcutaneous tissue

- Some intact lymphocytes present within cytoplasm of histiocytes ("emperipolesis")

Immunohistochemistry: positive S100, scattered positive CD68, negative CD1a

Diagnosis: Cutaneous Rosai-Dorfman disease

Investigation:

CBC: Hb 11.9 g/dL, Hct 35.9 %, WBC 8,600/cumm (N 75%, L 21%, Mono 3%, Eo1%), MCV 100.8 μm^3 , Platelet 344,000/cumm

Cr 0.52 mg/dL

LFT: normal

ANA, Anti-dsDNA: negative

Treatment:

Prednisolone 30 mg/day for 1 month then taper to 15 mg/day

Presenter: Panadda Darukarnphut, MD

Consultant: Ruedee Phasukthaworn, MD

Discussion:

Rosai-Dorfman disease (RDD) or sinus histiocytosis with massive lymphadenopathy (SHML) is a rare benign disorder of histiocytic proliferation. It was first described in 1969 by Rosai and Dorfman. Typically, RDD manifests in the second and third decades of life. African Americans are more often affected than Caucasians and a male predominance is present.¹ The etiology is remain

unknown, but two hypotheses have been proposed as follows: a disturbance of cell-mediated immunity and infectious agents including Epstein-Barr virus, human herpesvirus six, parvovirus B19, herpes simplex virus, *Brucella*, *Klebsiella rhinoscleromatis* and *Nocardia*.² RDD was characterized by extensive cervical lymphadenopathy associated with fever, polyclonal gammopathy, and leukocytosis with neutrophilia.¹ Lymphadenopathy appears in 87% of the patients and is often cervical, bilateral, massive and painless. Inguinal (25.6%), axillary (23.7%) and mediastinal lymph nodes (14.5%) may also be involved. Extranodal manifestations have been reported in 43% of cases. The most commonly involved extranodal sites include the skin, CNS, orbit and eyelid, upper respiratory tract, and less commonly, the gastrointestinal tract.^{3,4} Cutaneous manifestations are varied and appear as single or multiple macules, papules, plaques or nodules, with colors ranging from red-brown to yellow.^{5,6}

The cutaneous-only form of RDD (CRDD) is rare accounting for only 3% of reported RDD cases. A clinically distinct entity from RDD. Women with CRDD appear to be more affected than men, and most cases have been seen among Caucasian and Asian populations. In CRDD, patients typically present with normal laboratory data and no adenopathy. Lesions can vary, ranging from less than 1 cm to 30 cm or more at their greatest dimensions. Clinically, CRDD usually presents as erythematous or brownish infiltrated nodules or plaques with surrounding satellite papules.^{7,8} On dermoscopy, lesions classically resemble ovoid structures on an erythematous base with multiple yellowish structures in the periphery.^{9,10} The most common site of skin involvement is the extremities followed by the head and neck region. Most patients with CRDD are benign clinical course, with a frequent and spontaneous resolution of lesions.^{2,8,11}

The diagnosis of RDD is based on the correlation of clinical, serological, and histopathological findings to exclude other causes.

The classic histopathology of RDD and CRDD includes dense diffuse or nodular infiltrates of foamy histiocytes mixed with lymphocytes and plasma cells exhibiting emperipolesis. In extranodal RDD, increased amounts of fibrosis and fewer histiocytes are present in the lesions as compared with nodal RDD. Immunohistochemical testing shows strong and consistent positivity for S-100 protein and for CD68, but not for CD 1a.^{5,9,10}

The laboratory investigation for RDD should include rheumatoid factor, antinuclear antibody test, complete blood counts, liver and kidney function tests, immunoglobulin levels, and an erythrocyte sedimentation rate (ESR), screening for EBV, cytomegalovirus, HHV-6, HHV-8, and HIV. Imaging such as computed tomography (CT) scans of the neck, chest, abdomen, and pelvis to look for distant disease. The role of bone marrow biopsy is unclear, it is usually obtained because primary bone marrow disorders are included in the differential diagnosis of RDD.^{1,13,14}

There is no standard treatment for RDD due to benign clinical course and usually spontaneous resolving over 1–3 year. The treatment options include topical/ intralesional/ systemic glucocorticoids, acitretin, isotretinoin, dapsone, thalidomide, cytotoxic chemotherapy (eg. vincristine, vinblastine, methotrexate), interferon- α radiotherapy, pulsed dye laser and surgical excision.¹⁵⁻¹⁹

In summary, we present a case of middle age female who presented with indurated plaques and reddish-brown papules on extremities for 5 months. The clinical and histopathological findings suggest the diagnosis of cutaneous Rosai-Dorfman disease. She was treated by oral prednisolone 30 mg/day for 1 month and then tapered to 15 mg/day with partial improvement.

References

1. Dalia S, Sagatys E, Sokol L, Kubal T. Rosai-Dorfman disease: tumor biology, clinical features, pathology, and treatment. *Cancer Control* 2014;21:322-7.
2. Farooq U, Chacon AH, Vincek V, Elgart GW. Purely cutaneous rosai-dorfman disease with immunohisto-chemistry. *Indian J Dermatol* 2013;58:447-50.
3. Ma H, Zheng Y, Zhu G, Wu J, Lu C, Lai W. Rosai-dorfman disease with massive cutaneous nodule on the shoulder and back. *Ann Dermatol* 2015 Feb;27:71-5.
4. Maia RC, de Meis E, Romano S, Dobbin JA, Klumb CE. Rosai-Dorfman disease: a report of eight cases in a tertiary care center and a review of the literature. *Braz J Med Biol Res* 2014;48:1-12.
5. Becker M, Gaiser T, Middel P, Rompel R. Clinicopathologic challenge. Destombes-Rosai-Dorfman disease (DRDD) (sinushistiocytosis with massive lymphadenopathy). *Int J Dermatol* 2008;47:125-7.
6. Lu CI, Kuo TT, Wong WR, Hong HS. Clinical and histopathologic spectrum of cutaneous Rosai-Dorfman disease in Taiwan. *J Am Acad Dermatol* 2004;51: 931-9.
7. Leal PA, Adriano AL, Breckenfeld MP, Costa IS, de Sousa AR, Gonçalves Hde S. Rosai-Dorfman disease presenting with extensive cutaneous manifestation. *An Bras Dermatol* 2013;88:256-9.
8. Frater JL, Maddox JS, Obadiah JM, Hurley MY. Cutaneous Rosai-Dorfman disease: comprehensive review of cases reported in the medical literature since 1990 and presentation of an illustrative case. *J Cutan Med Surg* 2006;10:281-90.
9. Rodríguez-Blanco I, Suárez-Peñaranda JM, Toribio J. Atypical presentation and dermoscopic evaluation of cutaneous Rosai-Dorfman Disease. *Acta Derm Venereol* 2009;89:430-1.
10. Avilés-Izquierdo JA, Parra Blanco V, Alfageme Roldán F. Dermoscopic features of cutaneous Rosai-Dorfman disease. *Actas Dermosifiliogr* 2012;103:446-8.
11. Brenn T, Calonje E, Granter SR, Leonard N, Grayson W, Fletcher CD et al. Cutaneous Rosai-Dorfman disease is a distinct clinical entity. *Am J Dermatopathol* 2002;24:385-91.
12. Hsiao CH, Tsai TF, Yang TH, Liu CM. Clinicopathologic characteristics of Rosai-Dorfman disease in a medical center in northern taiwan. *J Formos Med Assoc* 2006;105:701-7.
13. Mehraein Y, Wagner M, Remberger K, Füzesi L, Middel P, Kaptur S et al. Parvovirus B19 detected in Rosai-Dorfman disease in nodal and extranodal manifestations. *J Clin Pathol* 2006;59:1320-6.