

---

## Case 30

### Acute pustular eruptions in pregnancy

---

Vipawee Ounsakul, M.D.  
Kunlawat Thadanipon, M.D.

**Patient:** A 14-year-old Thai girl from Bangkok

**Chief complaint:** Generalized pustular eruptions with fever for 3 days

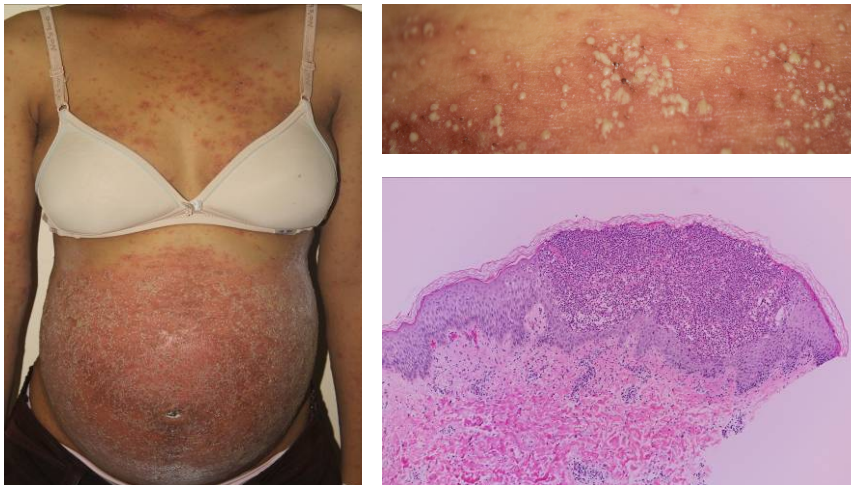
**Present illness:**

The patient was in the 24<sup>th</sup> week of her first gestation. She developed erythematous plaques on the abdomen 1 week before visiting our clinic. A few days later, they extended to the back and extremities. She also had a fever.

**Past history:** no underlying disease, no family history of psoriasis

**Skin examination:**

- Confluent scaly erythematous plaques studded with pustules on the abdomen
- Multiple pustules and erythematous papulopustules on the trunk and extremities



**Histopathology:** (S14-18212, left forearm)

There is a large subcorneal pustule filled with numerous neutrophils in association with superficial perivascular inflammatory-cell infiltrate.

**Direct immunofluorescence:** non-specific findings

**Diagnosis:** **Impetigo herpetiformis**

**Investigation:**

CBC: Hct 26.4%, WBC 13370 (N86%, L7%, M4%, B3%),  
Platelet 410,000/mm<sup>3</sup>, MCV 61.5

Creatinine 0.54 mg/dL

Liver function test: AST 16, ALT 14, GGT 15, ALP 13, TB 1.4, DB 0.4,  
TP 60.2 g/l, Alb 26.1 g/l

**Treatment:**

- Advice on the natural history and prognosis of the disease
- Advice for frequent fetal surveillance
- Oral prednisolone 30 mg per day (0.6 mg/kg/day) for 2 week, then slowly tapered down
- 0.1% triamcinolone acetonide milk lotion apply lesions twice daily
- Cold cream to be applied twice daily
- Oral dicloxacillin 500 mg four times daily for 1 week

**Discussion:**

Our patient was a 14-year-old primigravida with otherwise uncomplicated pregnancy. She developed generalized erythematous pustular eruptions in the 24<sup>th</sup> week of gestation. The physical examination findings were normal except for the widespread skin lesions on trunk and extremities. The histopathology revealed subcorneal pustules and DIF showed non-specific findings, so the diagnosis of impetigo herpetiformis was made.

Impetigo herpetiformis (IH) or gestational pustular psoriasis is a rare non-infectious acute pustular eruption which typically occurs during the third trimester of pregnancy. The term IH was first introduced by von Hebra in 1872 to describe 5 pregnant or puerperal women with acute pustular eruptions, intense fever, dry tongue and great prostration, of whom only one survived<sup>1</sup>. To date, only approximately 130 cases have been published to describe this disease entity<sup>2</sup>.

It is still controversial whether IH is a variant of generalized pustular psoriasis occurring in pregnancy or a separate pregnancy-specific disease. IH is now generally considered to be a variant of pustular psoriasis<sup>3-5</sup>.

The pathogenesis of IH is still unknown. It typically occurs in women with no pre-existing skin conditions or family history of skin diseases. Triggering factors that have been reported include hypocalcaemia, hypoparathyroidism, hypoalbuminaemia, stress and exposure to bacterial or other infection<sup>6</sup>. A genetic predisposition is also documented since there were case reports of twin sisters both developing IH during pregnancy<sup>7</sup>.

IH mainly afflicts pregnant women during the third trimester of pregnancy but it may also occur in the first and second trimester or puerperium<sup>8</sup>. Primiparous women are at the highest risk, although the disease tends to recur at an earlier gestational age with increased severity in the subsequent pregnancy<sup>6</sup>. IH usually resolves after delivery of the fetus, but may occasionally run a chronic course. The exacerbations of IH after certain stimuli such as oral contraceptives and menstruation have been reported<sup>9</sup>.

The diagnosis of IH is mainly based on typical clinical findings. The eruptions typically start symmetrically in flexural areas, below the breasts or around the umbilicus<sup>6</sup>. The lesions are erythematous plaques studded with sterile pustules at the margins in a circinate pattern and can spread centrifugally to become generalized with new pustules at the margins while older central pustules dry with desquamation or crusts<sup>1,6</sup>. Subungual pustules may be present and lead to onycholysis, or rarely onychomadesis<sup>10</sup>. In severe cases, there may be erosion of the mucous membranes, such as tongue, mouth and esophagus<sup>1</sup>. Associated constitutional symptoms may include fever, chills, malaise, diarrhea, nausea, vomiting, delirium and symptoms of tetany<sup>1</sup>.

Laboratory investigation may show common findings of leukocytosis, elevated erythrocyte sedimentation rate, hypocalcemia, hypoalbuminemia and low thyroid hormone levels. Although patients may have systemic symptoms, blood and pustules culture are generally sterile<sup>6</sup>. Immunohistochemistry is negative and there is no specific serology or autoantibodies noted in IH<sup>2,6,11</sup>.

The typical histopathology of IH shows parakeratosis, acanthosis, psoriasiform hyperplasia, intraepidermal spongiform pustules containing neutrophils and papillary dermal infiltration of lymphocytes and neutrophils<sup>2,7</sup>.

Early diagnosis and treatment is important because the more severe and longstanding the disease is the greater are the risks of maternal and fetal complications<sup>11</sup>. Maternal prognosis is usually favorable with early treatment and monitoring of complications including fluid and electrolyte imbalance, especially serum calcium to prevent sequelae of hypocalcemia such as seizures and tetany, as well as secondary infection and sepsis. Maternal cardiac and renal functions also need to be closely monitored. Fetal prognosis is less predictable, even in treated patients. Fetal mortality results from placental insufficiency which leads to intrauterine growth restriction, fetal abnormalities, stillbirth or neonatal death have been reported<sup>11</sup>. Frequent fetal surveillance with electronic monitoring and uterine artery Doppler ultrasound may predict placental insufficiency earlier and prevent adverse outcomes<sup>1</sup>.

Our patient was treated with oral prednisolone, oral antibiotics and topical corticosteroids. After treatment, marked improvement was noted and without abnormal findings on the recent fetal surveillance.

## References:

1. Y.H. Huang, Y.P. Chen, C.C. Liang, Y.L. Chang, C.C. Hsieh. Impetigo Herpetiformis with Gestational Hypertension: A Case Report and Literature Review. *Dermatology*. 2011; 222: 221--4.
2. Green M, Bragg J, Rosenman KS, Pomeranz MK. Pustular psoriasis of pregnancy in a patient whose dermatosis showed features of acute generalized exanthematous pustulosis. *Int J Dermatol*. 2009; 48: 299–303.
3. Lotem M, Katzenelson V, Rotem A, Hod M, Sandbank M. Impetigo herpetiformis: a variant of pustular psoriasis or a separate entity?. *J Am Acad Dermatol*. 1989; 20: 338–41.
4. Finch TM, Tan CY. Pustular psoriasis exacerbated by pregnancy and controlled by cyclosporin A. *Br J Dermatol*. 2000; 142: 582–4.
5. Breier-Maly J, Ortel B, Breier F, Schmidt JB, Hönigsmann H. Generalized pustular psoriasis of pregnancy (Impetigo herpetiformis). *Dermatology*. 1999; 198: 61–4.
6. Caroline J Shaw, Pensee Wu, Amir Sriemevan. First trimester impetigo herpetiformis in multiparous female successfully treated with oral cyclosporine. *BMJ Case Reports*. 2011 May 12.
7. Kubilay Vicdan, Zerrin Gökay, Turgut Var, Nuri Danisman, Oya Gökmen. Twin sisters with impetigo herpetiformis. *Eur J Obstet Gynecol Reprod Biol*. 1995; 63: 195-6.
8. Stephanie Lehrhoff, Miriam Keltz Pomeranz. Specific dermatoses of pregnancy and their treatment. *Dermatol Ther*. 2013; 26: 274–84.
9. G Chaidemenos, I Lefaki, A Tsakiri, O Mourellou. Impetigo herpetiformis: menstrual exacerbations for 7 years postpartum. *J Eur Acad Dermatol Venereol*. 2005; 19: 466–9.
10. Puig L, Barco D, Alomar A. Treatment of psoriasis with anti-TNF drugs during pregnancy: case report and review of the literature. *Dermatology*. 2010;220(1):71–76.
11. Vaughan Jones SA, Hern S, Nelson-Piercy C. A prospective study of 200 women with dermatoses of pregnancy correlating clinical findings with hormonal and immunopathological profiles. *Br J Dermatol*. 1999; 141: 71–81.
12. Kubra Bozdag, Serap Ozturk1, Murat Ermete. A case of recurrent impetigo herpetiformis treated with systemic corticosteroids and narrowband UVB. *Cutan Ocul Toxicol*. 2012; 31(1): 67–9.
13. Robinson A, Van Voorhees AS, Hsu S, Korman NJ, Lebwohl MG, Bebo BF Jr, Kalb RE. Treatment of pustular psoriasis: from the Medical Board of the National Psoriasis Foundation. *J Am Acad Dermatol*. 2012; 67: 279–88.
14. Qian-Qian Gao, Ming-Rong Xi, Qiang Yao. Impetigo Herpetiformis during Pregnancy: A Case Report and Literature Review. *Dermatology*. 2013; 226: 35–40.
15. Imai N, Watanabe R, Fujiwara H, Ito M, Nakamura. A Successful treatment of impetigo herpetiformis with oral cyclosporine during pregnancy. *Arch Dermatol*. 2002; 138(1): 128–9.