

### Case 6

A 25-year-old Thai female from Ubonratchathani

**Chief complaint:** Hypopigmented sclerotic patch with central dark-brown papules for 2 ½ years

**Present illness:** The patient presented with a hypopigmented sclerotic patch with central dark-brown papule for 2 ½ years. 3 years ago, she noticed a 3-mm brownish papule on her right cheek. She went to private clinic and was treated with laser ablation. After procedure, there was a residual of small brownish spot surrounded by atrophic scar. 6 months later, this lesion was surrounded by hypopigmented patch which gradually increased in diameter and induration. This lesion is asymptomatic. (Fig. )

**Past history:** She is healthy and not taking any medication. She is a computer technical officer who spends most of the time indoor. No smoking or drinking

**Family history:** No family history of any skin problem

#### **Physical examination:**

HEENT: not pale, no icteric sclerae

LN: not palpable

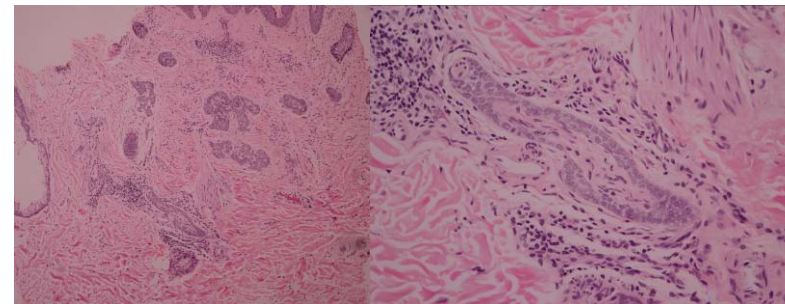
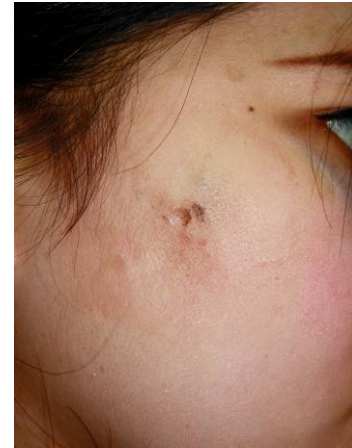Abdomen: no hepatosplenomegaly

#### **Skin examination**

- Brownish atrophic papules surrounded by ivory sclerotic plaque with raised border size 8×8 cm in diameter on the right cheek.
- No palmar or plantar lesion

#### **Histopathology:**

Multiple aggregates of atypical basaloid cells, some surrounded by clefts, in the upper dermis



#### **Investigation :**

**X-ray skull series :** no calcified falx cerebri, no jaw cyst

**MRI of Head and Neck:** no invasion of subcutaneous layer and adjacent structures

**Diagnosis:** Large basal cell carcinoma with neurotropism in young woman

**Treatment:** Wide excision with split thickness skin graft