

Case. 14

A 28-year-old Thai woman from Bangkok

Chief complaint: Asymptomatic orange-brown purpuric macules on right lower leg and spread to thigh.

Present illness: 2 years history of gradually spreading, asymptomatic yellow-brown purpuric macules in a patchy linear distribution on the right leg and spread to involve the thigh. No antecedent trauma and drug used.

Personal history: No known underlying disease

Family history: No family history of similar skin lesion

Physical examination: Multiple discrete well defined, yellow-brown purpuric macules in a patchy linear distribution over the extensor of the right lower leg and thigh. (Fig14.1, 14.2)

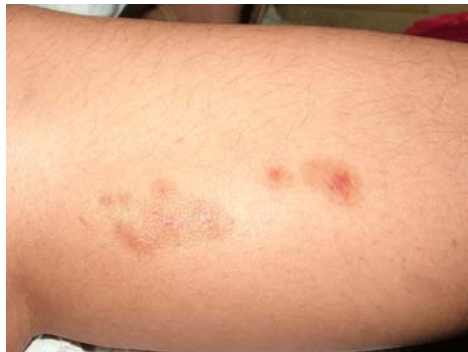

Fig. 14.1

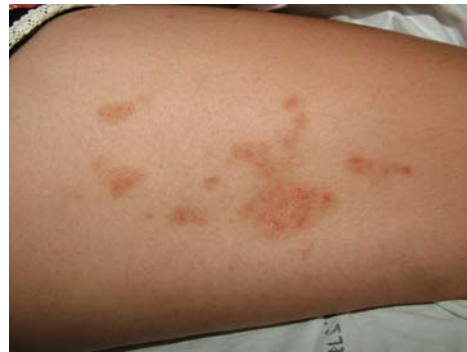

Fig. 14.2

Laboratory investigation: Nil

Histopathology (S09-07886) (Fig. 14.3, 14.4)

There are dense superficial lichenoid infiltrate of the lymphocyte and extravasated erythrocytes in the papillary dermis.

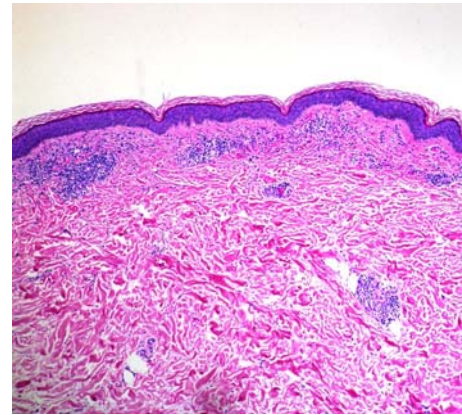


Fig. 14.3

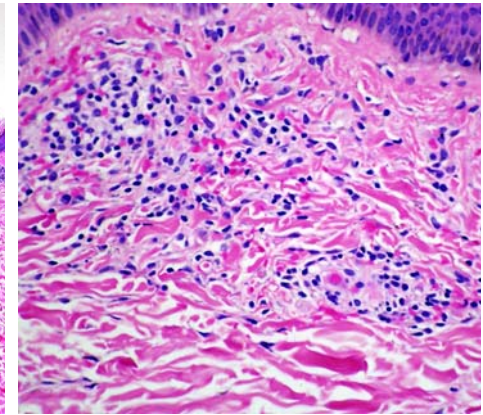


Fig. 14.4

Diagnosis: Segmental pigmented purpuric dermatoses

Presenter: Wannada Laisuan

Consultant: Natta Rajatanavin

Discussion:

Segmental pigmented purpuric dermatoses, also named unilateral linear capillaritis was first described in 1992 by Riordan¹ and was considered a rare variant of pigmented purpuric dermatoses². These conditions are characterized clinically by an extensive linear or segmental distribution of pigmented purpuric macules, mainly affecting adolescent boys and young men. These lesions are located predominantly on the lower extremities^{1,3}.

Pigmented purpuric dermatoses (PPD) are a group of chronic skin disorders of unknown cause characterized by petechiae, lichenoid papules, telangiectasia, and later development of pigmentation. They have been traditionally divided into five clinical entities: Progressive pigmented purpuric dermatoses, Purpura annularis telangiectodes, Lichen aureus, Pigmented purpuric lichenoid dermatosis and eczematidlike purpura of Doucas and Kapetanakis. The other rare and

unusual presentations include the itching purpura of Loewenthal, linear, granulomatous, quadrant, transitory and familial forms (Table 1) ².

Table 1. Classification of pigmented purpuric dermatosis

1. Purpura annularis telangiectodes (Majocchi disease)
2. Progressive pigmentary dermatosis (Schamberg's disease)
3. Pigmented purpuric lichenoid dermatitis (Gougerot-Blum disease)
4. Eczematid-like purpura (Doucas-Kapetanakis disease)
5. Itching purpura (disseminated pruriginous angioidermitis)
6. Lichen aureus (lichen purpuricus)
7. Unilateral linear capillaritis (quadrant capillaropathy)
8. Granulomatous pigmented purpura

The etiology is unknown. Proposed mechanisms include disturbance or weakness of the cutaneous blood vessels, leading to capillary fragility and erythrocyte extravasation ⁴.

Cell mediated immune response has also been proposed in the pathogenesis of PPD ⁴⁻⁵. Most of the infiltrating cells in the lesions were predominantly composed of helper – T cells and OKT6 – reactive cells, whereas the epidermis showed intercellular staining with human leukocyte antigen (HLA) – DR antibody and OKT6 antibody ⁵. Based on this study concluded that a cellular immune reaction, specifically the Langerhans cell, likely plays an important role in the pathogenesis.

The other mechanism is humoral immunity. This suggested pathogenesis is supported by direct immunofluorescent studies showing vascular deposition of C3, C1q, immunoglobulin M or immunoglobulin A ⁶.

Drug ⁷⁻⁸, venous hypertension ⁹, gravitational dependency are important cofactors that appear to influence disease presentation.

The categorization of pigmented purpuric dermatoses (PPD) as a form of cutaneous lymphoid dyscrasia has been suggested. Some evidence supports the idea that lichenoid variants of PPD may be precursors of mycosis fungoides, with similar histologic findings and clonal populations of lymphocytes ¹⁰.

In early lesions, there is perivascular and interstitial lymphocytic inflammation and extravasation of erythrocytes with endothelial swelling of superficial small vessels in the papillary dermis. In older lesions, there is less inflammation, and hemosiderin deposits are found in macrophages. Segmental pigmented purpuric dermatoses have a typical pathology of PPD ¹¹.

No medical intervention is of proven benefit for the treatment of the pigmented purpuric dermatoses, though withdrawal of suspected causes might help in some cases ¹². Oral bioflavonoid 50 mg twice daily and ascorbic acid 500 mg daily cleared three patients in a trial within 4 weeks ¹³.

Corticosteroids have been reported to be successful, in particular, triamcinolone spray or potent topical steroids. Systemic corticosteroids and cyclosporine are often effective but are not indicated due to the benign nature of the disorder.

Psoralen and ultraviolet A light and narrow band ultraviolet B have both been reported to clear lesions.

An encouraging effect of pentoxifylline, which is supposed to act at the level of T-cell adherence to endothelial cells and keratinocytes, has been described with a dose of 400 mg three times daily for 2–3 weeks (n = 4) ¹⁴⁻¹⁵.

Inclusion, PPD is a benign skin disease. At present, there is no known effective treatment for this disorder.

References

1. Riordan CA, Darley C, Markey AC, Murphy G, Wilkinson JD. Unilateral linear capillaritis. *Clin Exp Dermatol* 1992;17:182-5.
2. Sardana K, Sehgal VN. Pigmented purpuric dermatoses. *Int J Dermatol* 2004;43:482-8.
3. Mar A, Fergin P, Hogan P. Unilateral pigmented purpuric eruption. *Australas J Dermatol* 1999; 40:211-4.
4. Tristani-Firouzi P, Meadows KP, Vanderhooft S. Pigmented purpuric eruptions of childhood. a series of cases and review of literature. *Pediatr Dermatol* 2001; 18:299–304.
5. Aiba S, Tagami H. Immunohistologic studies in Schamberg's disease. *Arch Dermatol* 1988;124: 1058-62.
6. Schroeder T. Pigmented Purpuric Dermatoses. In: Freedberg IM, Eisen AZ, Wolff KF, Austen KF, Goldsmith LA, Katz SI, eds. *Fitzpatrick's Dermatology In General Medicine*, Vol.2, 6th. edn. New York: McGraw-Hill, 2008: 1633-37.
7. Kwon SJ, Lee CW. Figurate purpuric eruptions on the trunk: acetaminophen-induced rashes. *J Dermatol* 1998;25:756–8.
8. Adams BB, Gadenne AS. Glipizide-induced pigmented purpuric dermatosis. *J Am Acad Dermatol* 1999;41:827–9.
9. Newton RC, Raimer SS. Pigmented purpuric eruptions. *Dermatol Clin* 1985;3:165–9.
10. Magro CM, Schaefer T. Pigmented purpuric dermatoses: classification by phenotypic and molecular profiles. *Am J Clin Pathol* 2007;128:218-29.
11. Hamada T, Inoue Y. A case of zosteriform pigmented purpuric dermatoses. *Arch Dermatol* 2007;143:1183-4.
12. Filo V, Galbavy S, Filova A, Borecka D, Novotna V. Unilateral progressive pigmented capillaropathy (Schamberg's disease) of the arm. *Br J Dermatol*. 2001;144(1):190-1.
13. Rheinhold U. Treatment of progressive pigmented purpura with oral bioflavonoids and ascorbic acid: an open pilot study in 3 patients. *J Am Acad Dermatol* 1999;41: 207.
14. Wahba-Yahav AV. Schamberg's purpura: association with persistent hepatitis B surface antigenemia and treatment with pentoxifylline. *Cutis* 1994;54:205–206.
15. Kano T, Hirayama K, Orihara M, Shiohara T. Successful treatment of Schamberg's disease with pentoxifylline. *J Am Acad Dermatol* 1997;36:827–30.