

## CASE 19

A 41-year-old Thai woman from Bangkok.

### Chief complaint:

Solitary tender mass on right thigh for 5 months.

### Present illness:

She developed whitish cauliflower ulcerated mass on her right thigh which has had chronic burn scar, accompanied with very sharp pain and itching for 5 months. The lesion gradually increased in size and no history of trauma.

### Past history:

She has generalized burn scars and was taken skin grafting on her lower extremities 20 years ago, she is otherwise healthy.

### Family history:

nil

### Physical examination:

A healthy Thai woman, not pale, no jaundice.

LN: no lymphadenopathy

Heart: normal S1, S2, no murmur

Lung: clear

Abdomen: a transverse linear scar on sub-umbilical area, no hepatosplenomegaly

Skin: solitary well defined border ulcerating mass, 4 cms in diameter, on right thigh.

### Investigation :

CBC: and electrolyte : WNL

LFT: WNL

Anti – HIV: negative

### Histopathology: S05-18114

Downward epithelial proliferation of atypical squamous cell extending into the deep reticular dermis.

Atypical cells show large hyperchromatic and pleomorphic nuclei with atypical mitotic figures. Scar in the underlying dermis.

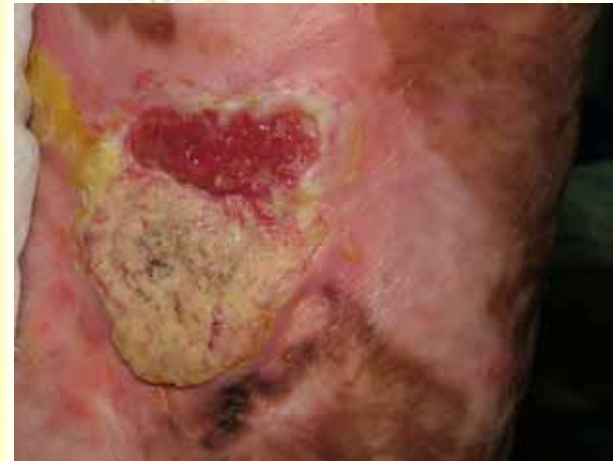

Fig. 19.1

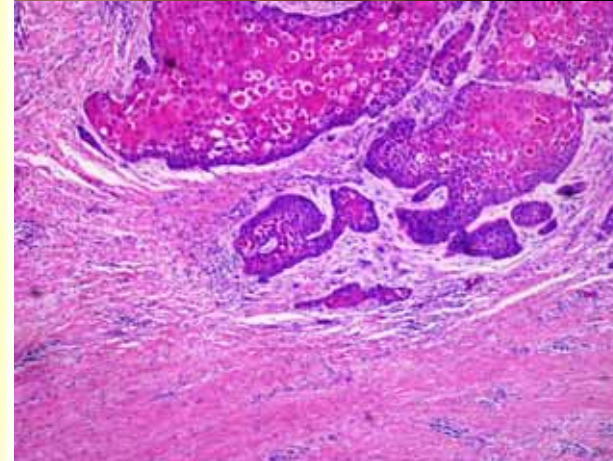


Fig. 19.2

### Swab culture :

*Pseudomonas aeruginosa*, sensitivity to Cefoperazone, Ceftazidime, Cefipime, resistant to Gentamicin

**Diagnosis :** Squamous cell carcinoma on burn scar

**Presenter :** Diana Sripornkitkachorn

**Consultant :** Somneuk Kamtavee

**Treatment :** wide excision with STSG

**Discussion:**

Squamous cell carcinoma (SCC) is a malignant neoplasm derived from suprabasal epidermal keratinocytes. Burn or chronic heat exposure may predispose to SCC. It is estimated that 2% of burn scars undergo malignant transformation and SCC is the most common type cancer.

The pathogenesis of carcinoma arising in a chronic scar is not known. Proposed mechanisms include production of a carcinogenic toxin with the burn injury; immunologic privilege within scar allowing unchecked tumor growth; multistep carcinogenesis and burn-induced DNA damage leading to malignant transformation. Characteristic of the burn scar that predispose to malignant transformation induced a prolong healing phase, repetitive trauma, and reject graft site.

SCC arising in scars typically begin decades after injury with skin breakdown and persistent erosion. Most commonly this occurs on the lower extremities at sites of chronic pyogenic or venous stasis ulcers. Gradually there is acquisition of nodularity, although detection is often delayed because of concealment by surrounding indurated scar tissue. The development of increase pain, drainage, or bleeding alone should raise concern and warrant further investigation. In this case, SCC was developed on her right thigh that she had burn scars.

The treatment modalities of SCC are non-excisional ablative techniques, Moh surgery, conventional surgery excision and radiation. Treatment selection is largely directed by assessment of tumor risk for recurrence and metastasis. Excisional surgery is a mainstay of therapy for many low risk non-melanoma skin cancers and a number of high-risk tumors in which the main high-risks feature is size. In this case, she was done wide excision with skin grafting. Radiotherapy should not be performed because this excision was free all surgical margin. Patients who developed SCC on burn scars, are supposed to be followed up regularly between 3 and 12 months to avoiding recurrence.

**References:**

1. Douglas G, David JL. Squamous Cell Carcinoma. In: Freedberg IM, Eisen AZ, Wolff K, Austen KF, Goldsmith LA, Katz SI, eds. *Dermatology in general Medicine*. 6<sup>th</sup> ed. McGraw-Hill, 2003: 737-46.
2. Stanley, Miller, Margaret M. Actinic keratosis, basal cell carcinoma and squamous cell carcinoma. In: Jean LB, Joseph LJ, Ronald PR, Thomas DH, Jose MM, eds. *Dermatology*. Mosby, 2003:1677-96.
3. Gul U, Kilic A. Squamous cell carcinoma developing on burn scar. *Ann Plast Surg*, 2006;56(4):406-8.
4. Mofikoya BO, Oyeneyin JO, Upboro OA, Daramola AO. Burn scar carcinoma: two case reports and review of literature. *Niger Postgrad Med J* 2006;13(1):66-8
5. Kowal-vern A, Criswell BK. Burn scar neoplasms: a literature review and statistical analysis. *Burns* 2005;31(4):403-13. Epub 2005 Apr 1.
6. Jellouli-Elloumi A, Kochbati L, Dhraief S, Ben RK, Maalej M. Cancers arising from burn scars: 62 cases. *Ann Dermatol Venereol*. 2003 Apr; 130(4):413-6.

Ramathibodi Hospital  
Interhospital Dermatology Conference  
August 18, 2006