

Ramathibodi

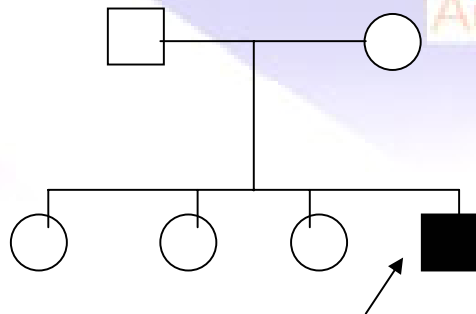
Case 14

A 34-year-old Thai man from Bangkok

Chief Complaint Asymptomatic multiple skin-colour papules for 20 years.

Present illness Twenty years ago he developed asymptomatic multiple skin-colour papules distributed at Rt. groin. The lesions gradually increase in number and disseminated to trunk, neck, upper and lower extremities.

Family History: Nil



August 15, 2003

Underlying disease schizophreniform disorder

Current Medication Perphenazine(8) bid
Artane(2) bid

Physical examination WNL

Dermatologic exam Generalized, skin-colour, tiny flat-topped papules, 1-3mm in diameter, on trunk and extremities with some dome-shaped papules.

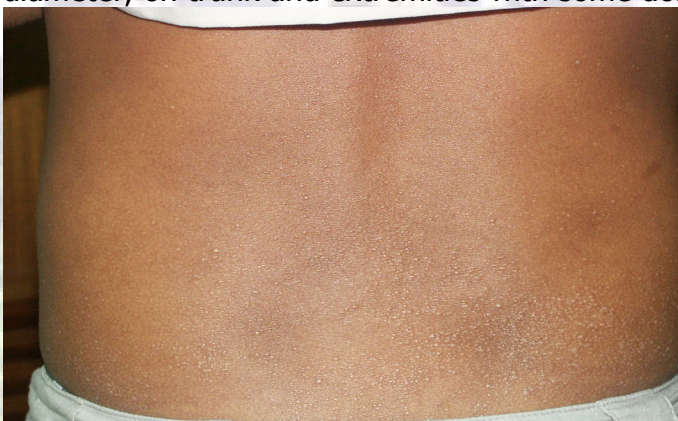

Fig.1

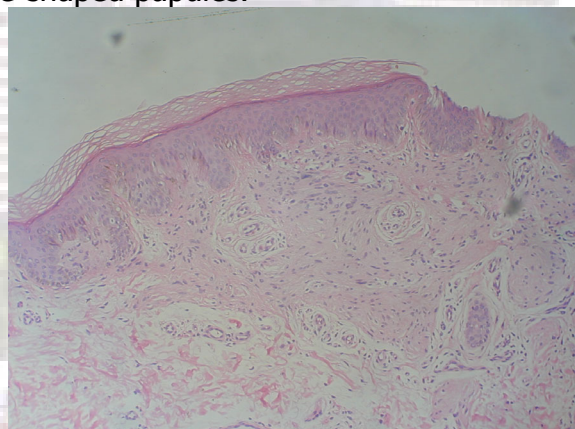


Fig.2

Skin Biopsy(s03-9244)

- thickened papillary dermis covered by hyperplastic epidermis
- small oval and spindle-shaped cells with elongated wavy nuclei arranged among thin collagen strands, embedded in loose matrix
- increased number of small blood vessels

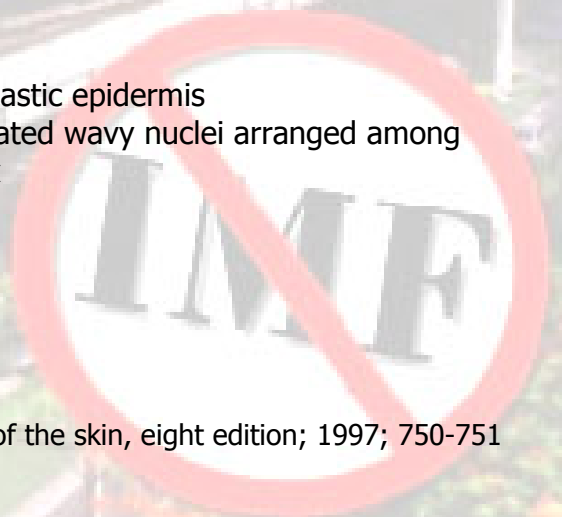
Diagnosis Trichodyscoma

Presenter Prachiya Jewhasuchin

Consultant Somyot Charuwichitratana

Reference

1. David Elder, Rosalie Elenitsas: Lever's Histopathology of the skin, eighth edition; 1997; 750-751



Ramathibodi Hospital

August 15, 2003

2. Hermann pinkus, Trichodiscoma.J Invest Dermatol.1974 Aug;63(2),212-218
3. Balus L, Crovato F, Breathnach As.Familial Multiple Trichodiscomas.J Am Academy Derm.1986;15:603-7
4. Rook/Wilkinson Textbook of Dermatology, sixth edition, Vol2, 1696



Interhospital Dermatology Conference