

Ramathibodi

Hospital

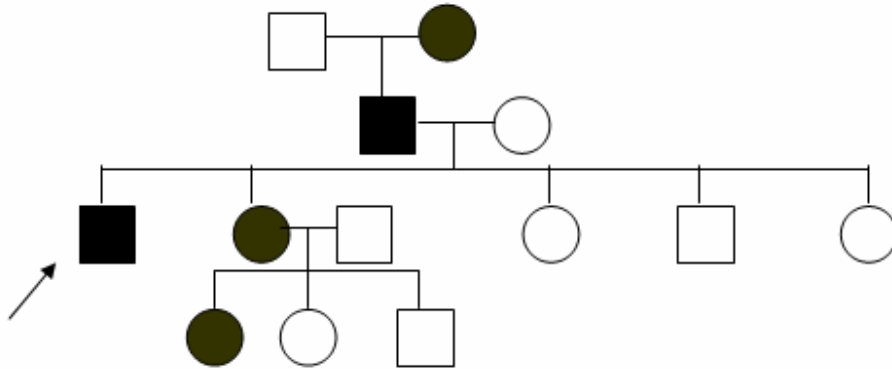
Case 9

A 56-year-old man from Aungthong

Chief complaint Generalized, hyperkeratotic, confluent brownish papules on seborrheic areas

Present illness The patient was referred from Aungthong hospital with the history of 10 year generalized hyperkeratotic papules on chest, back, ears. The lesions are moderately pruritic and gradually progressed accompanied with nail abnormality. He has no underlying disease and did not take any medication.

Pedigree



Physical examination

Generalized, hyperkeratotic, confluent brownish papules some coalesce into large plaques distributed on seborrheic areas (scalp, ear, chest, back)

Oral cavity: multiple small cobblestone-like papules on hard palate

Nail : v-shaped scalloping and subungual thickening

Hair : normal

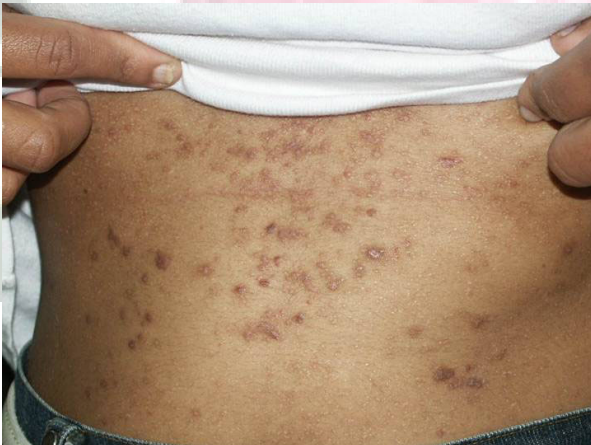

Fig.1

Lab Investigation Unremarkable

Genetic investigation ATP2A2, Chromosome 12 q

Histopathology (SL 41-2677)

- Small intraepidermal clefts filled with acantholytic dyskeratotic cells or focal acantholytic dyskeratosis (FAD).
- Clefts involved suprabasal and granular cell layers.
- No vesicles or inflammation.

Ramathibodi

Diagnosis
Presenter
Consultant

Darier's disease
Prachiya Jewhasuchin
Siripen Puavilai

Hospital

August 15, 2003

Reference

1. Cooper SM, Burge SM. Darier's Disease: Epidemiology, Pathophysiology, and Management. Am J Clin Dermatol 2003;4(2):9105.
2. Heo EP, Park SH, Yoon TJ, Kim TH. Induction of Darier's disease by repeated irradiation by ultraviolet B; protection by sunscreen and topical ascorbic acid :J Dermatol 2002 Jul;29(7):455-8.
3. Stojanovic S, Poljacki M, Jovanovic M, Tasic S. Stojanovic S, Poljacki M, Jovanovic M, Tasic S: Darier's disease--a familial case report. Med Pregl 2001 Jul-Aug;54(7-8):375-9.
4. Tavadia S, Mortimer E, Mature .Genetic epidemiology of Darier's disease: a population study in the west of Scotland : Br J Dermatol. 2002 Jan;146(1):107-9.
5. Wicks G. Meeting the complex care needs of a patient with Darier's disease: J Wound Care 2002 Oct;11(9):330-2.

Interhospital
Dermatology
Conference