

Case 14

A 31-year-old Thai woman from Bangkok

Chief complaint Coarse and slow growing hair for 3 years.

Present illness Her hair was becoming kinky, coarser in texture and had stopped growing since she was 28. These changes occurred initially on the posterior part of the scalp and subsequently spread to involve the entire scalp. Hair loss had commenced in affected areas. The body hair had unchanged.

Past history Her hair had been perfectly straight and normal until the age of 28 years. She had not undergone any x-ray treatment nor did she report any external trauma. Her medical history was unremarkable.

Family history Nil

Physical Examination

On examination revealed lusterless, kinky hair resembling pubic hair in the entire scalp hair. There was noticeable alopecia in affected areas.

On naked-eye examination, hairs presented twisted and tortuous appearance at 2 to 5 cm from the emergence of the hair

- The longest hair is 16.5 cms.
- Hair loss is about 90-110 /day.
- Normal nails and skin findings



Fig. 14.1

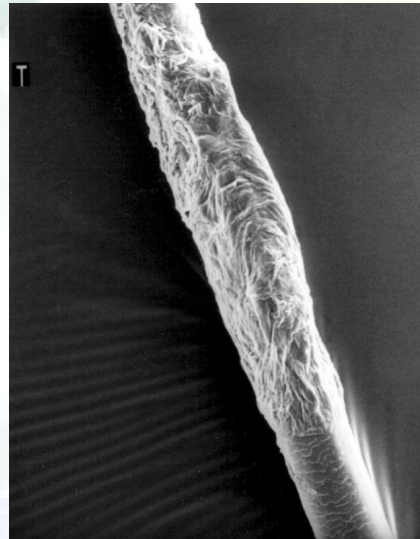


Fig. 14.2

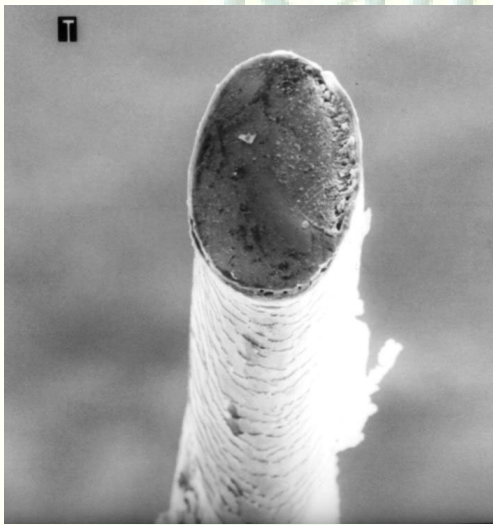


Fig. 14.3

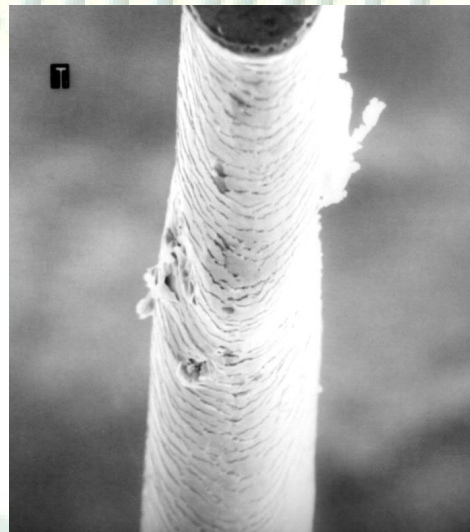


Fig. 14.4

Hair investigation

Normal hair growth rate

Trichogram

Hair from frontal scalp (36 hairs)

Anagen : Telogen = 16 : 20 (telogen 55.6%)

Hair from occipital scalp (46 hairs)

Anagen : Telogen = 26 : 20 (telogen 43.5 %)

scanning electron microscope(SEM)

- 1.partial twisting of the hair shaft on its longitudinal axis
- 2.shallow canalicular grooves
- 3.flattening of the hair shafts
- 4.cross-section : elliptical shape instead of circular shape

Diagnosis Acquired progressive kinking of the hair

Presentor Songsuda Phongsuwan

Consultant Somyot Charuwichitrattana

Reference

1. Wise F,Sulzberger MD. Acquired progressive kinking of the scalp hair accompany by changes in its pigmentation:correlation of an unidentified group of cases presenting circumscribed areas of kinky hair. Arch Dermatol Syph 1932;25:99-110.
2. Balsa RE,Ingratta SM,Alvarez AG. Acquired kinking of the hair: a methodologic approach. J Am Acad Dermatol.1986;15:1133-1136.
3. Rebora A,Guarrera M. Acquired progressive kinking of the hair. J Am Acad Dermatol. 1985;12:933-936.
4. Coupe RL,Johnston MM. Acquired progressive kinking of the hair: structural changes and growth dynamics of affected hairs. Arch Dermatol.1969;100:191-195.
5. Mortimer PS,Gummer C,English J,Davber PR. Acquired progressive kinking of the hair. Arch Dermatol.1985;121:1031-1033.
6. Esterly NB,Lavin MP,Garancis JC. . Acquired progressive kinking of the hair. Arch Dermatol.1989;125:813-815.