

# Ramathibodi

## Case 9

August 17, 2001

A 19 year-old female student from Bangkok

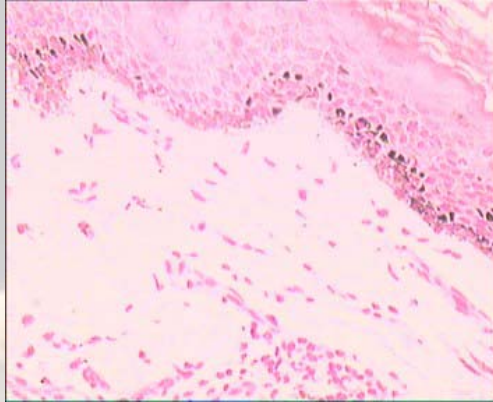
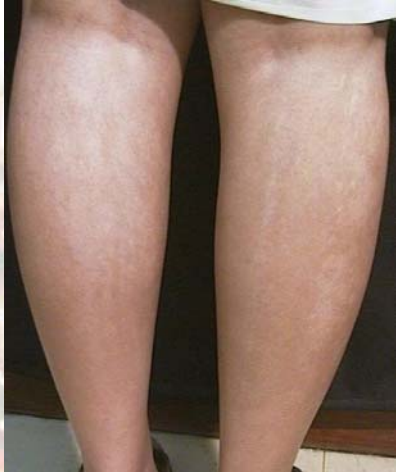**Chief complaint** Patchy depigmentation of the skin on the trunk and extremities

**Present illness** At 4 years of age, she developed asymptomatic white streaks, which gradually progressed

**Past history:** She is healthy, with no history of serious illness and a past history of normal childhood development. Average grade in study

**Family history:** No family history of similar skin lesions

**Physical examination** Multiple linear, whorled, and confluent hypopigmented macules and patches, with no scale on dorsum of the arms, thighs and lower back, along the lines of Blaschko



**Histopathology:** (S01-2614)

Mild superficial perivascular infiltration of lymphocytes and mild perifollicular fibrosis

**Diagnosis:** *Hypomelanosis of Ito*

**Presenter:** Wiwat Chareonkul

**Consultant:** Penpun Wattanakrai

## Reference:

1. Ruggieri M, Pavone L, Hypomelanosis of Ito : clinical syndrome or just -phenotype? *J Child Neurol.* 2000 Oct;15(10): 635-44
2. Kuster W, Konig A, Hypomelanosis of Ito : no entity, but a cutaneous sign of mosaicism. *Am J Med Genet.*1999 Aug 6;85(4): 346-50
3. Haenen I, Vanquickenborne L, Kerre S, Degreef H. Hypomelanosis of Ito. *Dermatology.* 1998; 196(4): 467-9.