

## Case 6

August 17, 2001

A 46-year-old Thai gentleman from Bangkok.

**Chief complaint** Two asymptomatic erythematous nodules over the left preauricular area.

The larger lesion appeared one year previously followed by the smaller one 9 months later.

The lesions slowly increased in size.

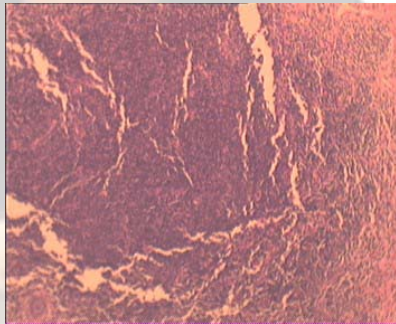
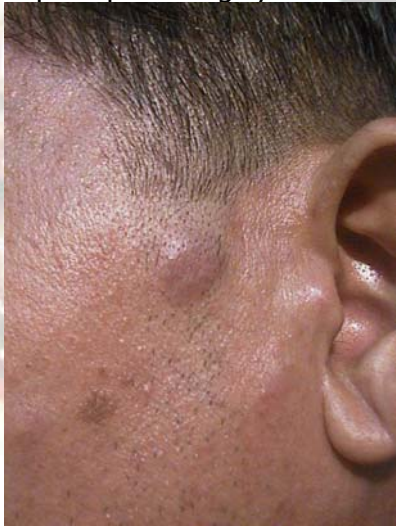**Past history** Nil

**Family history** Nil

### Physical examination

**Skin :** Two asymptomatic erythematous nodules at left cheek.

**Lymph node :** Lymphadenopathy of preauricular lymph nodes both sides and left superior cervical lymph node, 1-2 cm. in diameter. No hepatosplenomegaly.



### Histopathology (s01-09170 )

- Dense, nodular lymphocytic infiltrate, with a hint of lymphoid follicles
- Top- heavy infiltrate
- No epidermal change

**Diagnosis** Lymphocytoma cutis

**Presenter** Songsuda Phongsuwan

**Consultant** Siripen Puavilai

### References

1. Gilliam AC, Wood GS. Cutaneous lymphoid hyperplasias. *Semin Cutan Med Surg.* 2000;19: 133-41.
2. Cerroni L, Kerl H. Diagnostic immunohistology: cutaneous lymphomas and pseudolymphomas. *Semin Cutan Med Surg.* 1999;18:64-70.
3. Ploysangam T, Breneman DL, Mutasim DF. Cutaneous pseudolymphomas. *J Am Acad Dermatol.* 1998;38:877-95.