

August 17, 2001

A 60 year-old woman from Saraburi

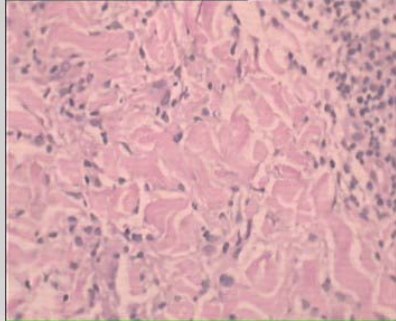
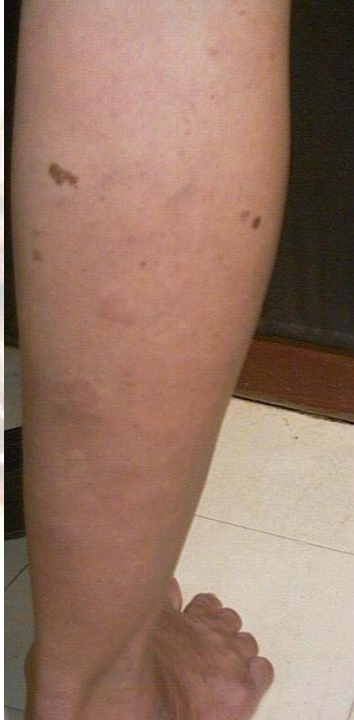Chief complaint Multiple red papules on both lower legs

Present illness 5 years PTA, she noticed occurrence of asymptomatic, erythematous papules, which gradually increase in number on both lower legs

Past history Nil

Family history Nil

Physical examination Multiple shiny, flat top, non-scaly erythematous papules and plaques, distributed on lower legs and arms with some annular, arciform lesions



Histopathology: S01-4091

There is diffused infiltration of lympho-histiocytes, in which lymphocytes altered between the collagen bundle with mucin deposit

Diagnosis: 17, 200 *Granuloma annulare*

Presenter: Wiwat Chareonkul

Consultant: Siripen Puavilai

Reference:

1. Vasquez-Lopez F, Gonzalez-Lopez MA. Localized granuloma annulare and autoimmune thyroiditis: a new case report. *J Am Acad Dermatol.* 2000 Nov; 43(5pt2): 943-5.
2. Granel B, Serratrice J. Chronic hepatitis C virus infection associated with a generalized granuloma annulare. *J Am Acad Dermatol.* 2000 Nov; 43 :918-9.
3. Mutasim DF, Bridges AG. Patch granuloma annulare: clinicopathologic study of 6 patients. *J Am Acad Dermatol.* 2000 Mar; 42(3): 417-21.