

## Case 2c

August 17, 2001

A 34-year-old Thai woman from Choburi

**Chief Complaint:** Multiple tiny brownish papules on trunk and extremities for 3 years

**Present illness :** She has had a 3-year history of multiple tiny brownish papules scattered on both arms, legs and back. The lesions were sometimes itched when sweating and bled on scratching.

1 month PTA, she developed small brownish papules on both conchas

**Past history:** Nil

**Family history :** Nil

### Physical examination

GA: A Thai middle- aged healthy woman, not pale, no jaundice

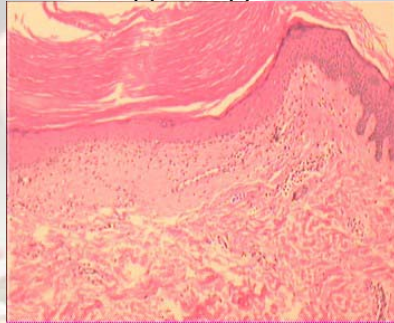
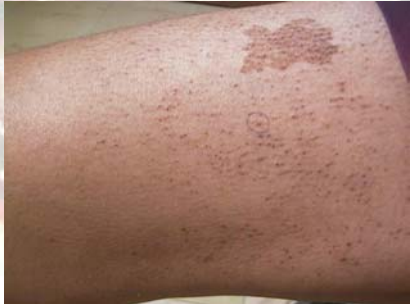HEENT: Small brownish papules on both conchas

Heart: Normal S1, S2, no murmur

Lung: Clear

Abdomen: No hepatosplenomegaly

Skin: Multiple tiny brownish papules scattering on arms, legs, back and both conchas. Some lesions are in linear, rippled appearance.



**Diagnosis:** Lichens amyloidosis

**Presenter:** Sutasee Tunsuriyawong

**Consultant:** Penpun Wattanakrai

## Reference

1. Bourke J F. Diffuse primary cutaneous amyloidosis. Br J Dermatol 1992; 127: 641-4.
2. Harahap M, Marwali MR. The treatment of lichens amyloidosis. Dermatol Surg 1996; 24(2): 251-4.