

August 17, 2001

## Case 2a

A 30 – year-old Thai man , from Bangkok

**Chief complaint** : asymptomatic diffuse hypopigmentation and hyperpigmentation on trunk and extremities for 10 years

**Present illness** : He has had a 10 – year history of asymptomatic diffuse hyperpigmented macules with numerous spotted hypopigmented macules on trunk , back and all extremities. The lesions progressed gradually to entire body area.

**Past history:** nil

**Family history:** nil

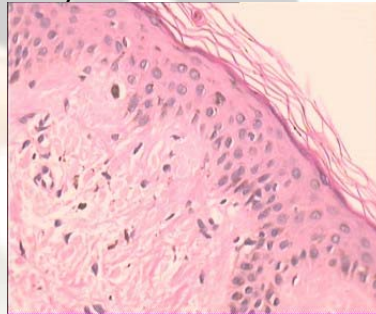
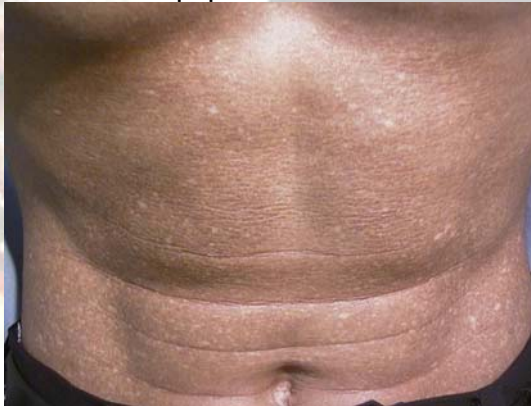**Physical examination** A healthy Thai man, not pale , no jaundice

HEENT WNL

Heart & Lung WNL

Abdomen no hepatosplenomegaly

Skin Generalized asymptomatic hyperpigmented and hypopigmented macules and papules distributed on entire body area.



## Histopathology (slide no. s00-14800)

- small homogeneous eosinophilic globules in the dermal papillae
- Melanophages and stellate fibroblast associated within the globules

**Diagnosis** Cutaneous dyschromic amyloidosis

**Presenter:** Wisuttida Taechotirote

**Consultant:** Siripen Puavilai

## Reference

1. Shin-ichi Moriwaki ,M.D. et al. Amyloidosis Cutis Duschromica , Arch Dermatol 1992 ; 128 : 966-970
2. J.F.Bourke et al . Diffuse primary cutaneous amyloidosis ,Br J Dermatol 1992 ; 127 : 641-644
3. Chu – Kwan Wong . Cutaneous amyloidosis ,Inter J Dermatol 1987 ; 26: 273-277