

August 17, 2001

A 49 year-old Thai woman from Nakornrajchasma.

Chief Complaint: Generalized pruritic papules for 1 year

Present illness : She had a one-year history of variable sized faintly erythematous pruritic papules on her trunk and extremities. The lesions rapidly increased in number over a short time , with dissemination following the initial expression.

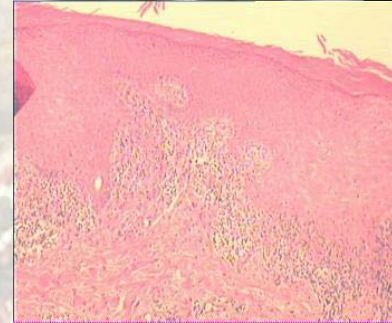
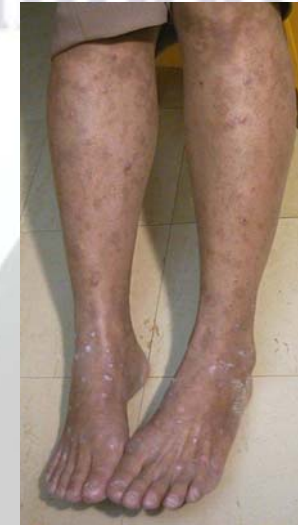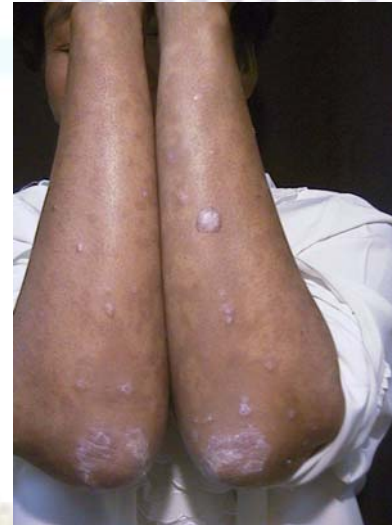Past history: 4 months before these lesions started , she had the history of using curcuma and developed generalized allergic rash . She was treated with antiallegic and antiinflammatory drugs . Hyperpigmented macules were noticed after resolution .

Family History nil

Physical Examination:

Skin generalized symmetrical discrete variable sized flat - topped faintly erythematous papules with superficial whitish scales on trunk and extremities. Hyperpigmented macules were also seen on trunk and extremities

Scalp	WNL
Nail	WNL
Oral mucosa	WNL



Histopathology :

- Dense band-like lymphocytic infiltrate with melanophages, obscuring the dermoepidermal interface.
- Sawtooth epidermal hyperplasia
- Hypergranulosis with wedge-shaped foci
- Compact orthokeratosis

Diagnosis: lichen planus.

Presenter: Prachiya Jewhasuchin.

Consultant: Siripen Puavilai.

Ramathibodi

Hospital

References 2001

1. Thompson DF , Skaehill PA . Drug - induced lichen planus : Phamacotherapy 1994 ; 14(5) : 561 - 571.
2. Ellgehausen P , Elsner P Bur G . Drug - induced lichen planus : Clinical Dematol 1998 ; 16(3) : 325 - 32.
3. Katta R Lichen Planus Am Fam Physician 2000 ; 61(11) : 3319-24 , 3327-8.
4. Lee CW , Yoon JY . Lichen planus antigen and antibodies in patient with generalized lichen planus : J Korean Med Sci 1987 ; 2(4) : 259-62.
5. Shuttleworth D , Grahm - Brown RA , Campbell AC. The autoimmunu background in Lichen panus : Br J Dermatol 1986 ; 115 (2) : 199 - 203.

Ramathibodi

Hospital

August 17, 2001