

## Case 1a

A 54-year-old Thai woman, from Bangkok

**Chief Complaint:** Generalized alopecia for 10 years

**Present illness:** She presented with generalized hair loss for 10 years. No history of fever, prodromal symptoms or other skin lesions. During 5 months of treatment (3% Minoxidil), the lesions had progressed to hyperkeratotic papules on shiny scalp.

**Past history:** Underlying Diabetes mellitus, Hypertension, Ischemic heart disease for 2 years.

**Family History** nil

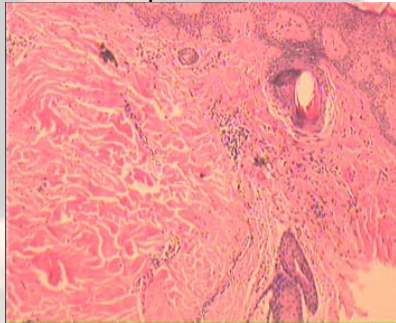
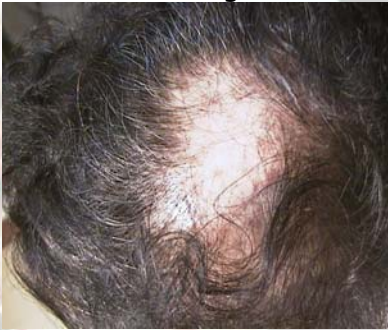**Physical Examination:**

Scalp shiny scalp with perifollicular hyperkeratotic papules and thinning hair

Skin, Oral mucosa and Nails Normal

Other hair bearing area

No alopecia



**Histopathology:** Slide No. S01 – 5672

Lymphocytic infiltration and fibrosis along hair follicle, partly obscuring it. Infundibular atrophy and plugging by orthokeratotic cells. Fibrotic tracts in older lesion.

**Diagnosis:** Lichen planopilaris

**Presenter:** Varaporn Putharayutawat

**Consultant:** Somyot Charuwichitratana

August 17, 2001

## References

1. Rodney D. Sinclair, Cedric C. Banfield, Rodney P.R. Dawber. Handbook of disease of the hair and scalp. 1st ed. 1999:95-125
2. Thomas B. Fitzpatrick, Irwin M. Freedberg, Arthur Z. Eisen, et al. Fitzpatrick's Dermatology in general medicine. 5th ed. 1999:566-567
3. David A. Mehregan, Harriet M. Van hale, Sigfrid A, et al. Lichen planopilaris: Clinical and pathologic study of 45 patients. J Am Acad Dermatol; 1992;27:935-42
4. Demetris Ioannides, Jean-Claude Bystryk. Immunofluorescence abnormalities in lichen planopilaris. Arch Dermatol; 1992;128:214-16
5. Steven Kossard, May-Sen Lee, Barbara Wilkinson. Postmenopausal frontal fibrosing alopecia: A frontal variant of lichen planopilaris. J Am Acad Dermatol; 1997;36:59-66
6. Martin S. Zinkernagel, Cand Med. Fibrosing alopecia in a pattern distribution. Arch Dermatol; 2000;136:205-11