

## Case 16

A 26 year-old Thai woman

**Chief Complaint:** Multiple dark brown papules on trunk and extremities for 2 year

**Past history :** 2 years PTA, she developed multiple asymptomatic, firm, dark brown papules on her back and both legs which later progressed to her left arm

She went to the dermatologist and one lesion was excised for histopathology. It showed dermal fibrosis suggestive of dermatofibroma

2 months later, she developed an erythematous rash on the malar area and had a 1-month history of arthralgia, alopecia and oral ulcer.

She was investigated and diagnosed as SLE ; criteria included malar rash, oral ulcer, FANA +, anti-DNA +

**Physical examination:** Multiple discrete dark brown, firm elevated papules, size 0.5-1 cm. in diameter distributed on back, left arm, left leg and right thigh.

### Investigation

CBC : WNL, ESR 95 mm/hr

UA : yellow, sp. gr 1.025, prot 1+ glu neg, wbc 15-20/HPF, sq epi >20/HPF

24 hr urine prot = 0.2g

ANA : homogenous pattern titer > 1:256 and rim pattern titer 1:16

Anti-DNA : positive titer 1:160

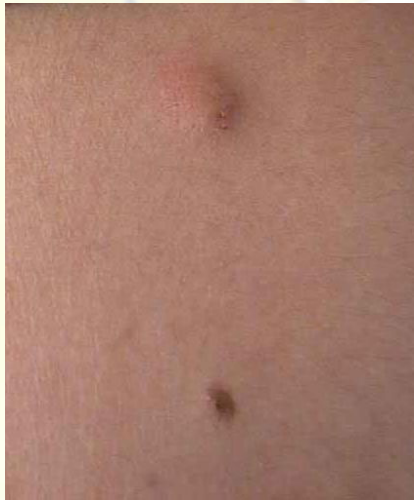

Fig. 16.1

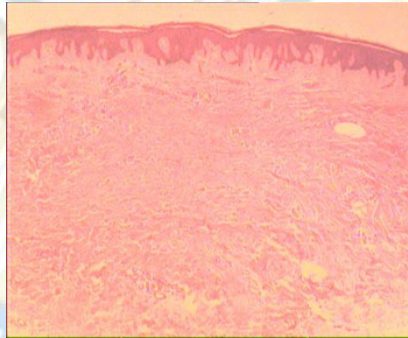


Fig. 16.2

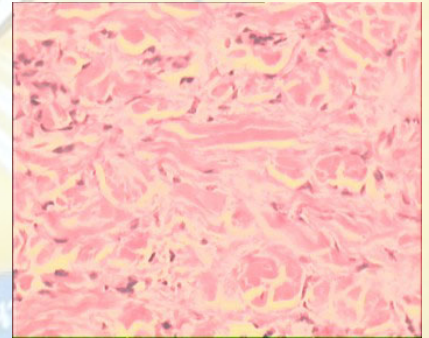


Fig. 16.3

### Histopathology ( slide no. 40-0208 )

- Haphazard arrangement of increased fibroblasts and associated coarse collagen
- Fibroblast at periphery appear to encircled thickened collagen bundles
- Absent epithelial adnexal structures
- Epidermal hyperplasia and hyperpigmentation

**Diagnosis:** Multiple dermatofibromas in a patient with SLE

**Presenter:** Chanisada Tuchinda, M.D.

**Consultant:** Siripen Puavilai, M.D.

### References

1. Lu I, Cohen PR, Grossman ME. Multiple dermatofibromas in a woman with HIV infection and systemic lupus erythematosus. J Am Acad Dermatol 1995;32: 901-3
2. Lin RY, Landsman L, Krey PR, Lambert WC. Multiple dermatofibromas and systemic lupus erythematosus, Cutis 1986;37: 45-7

August 20, 1999

Ramathibodi hospital

Ramathibodi Hospital