

## Case 9

A 28-year-old Thai woman

**Chief Complaint:** She had asymptomatic multiple discrete papules at inner side of left pinna for 2 weeks.

**Present illness:** 2 weeks PTA she noticed asymptomatic multiple papules on inner side of her left pinna. These papules are not increase in size and number.

**Past History:** Nil

**Family History:** Nil

**Physical examination:** Multiple discrete shiny skin colored papules 1-2 mm in diameter located on inner side of left pinna.

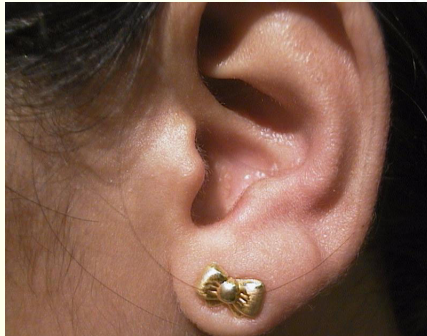

Fig. 9.1

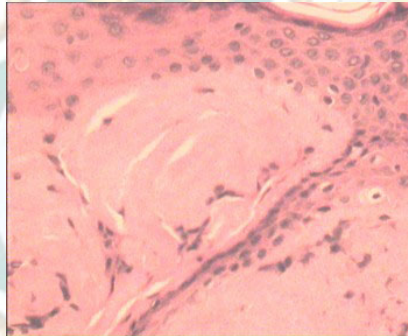


Fig. 9.2

**Histopathology :** (slide No. 99-9666)

- Large globular deposit of homogeneous amphophilic material at the broadened dermal papillae
- Papillated epidermal hyperplasia with hyperkeratosis
- Stellate fibroblasts, melanophages and small blood vessels associate with the globules

**Diagnosis :** Lichen amyloidosis at auricular concha

**Presenter:** Patra Phimolsarnti, M.D.

**Consultant:** Siripen Puavilai, M.D.

### Reference :

1. Panarese, A., Roland, N.J., Green B. Primary amyloidosis of the external auditory canal: case report. J laryngol-otol 1994; 49-50
2. Hicks, BS, Weber PJ, Hashimoto K, et al. Primary cutaneous amyloidosis of the auricular concha. J Am Acad Dermatol 1998;18:19-25

*Interhospital  
Dermatology  
Conference*

August 20, 1999