

Interhospital Dermatology Conference

Case 15

A 56-year-old female.

C/C : Multiple papular lesions on trunk.

P/I : She noticed persistent multiple asymptomatic skin - coloured papules since she was 14 years old. Some lesions regressed spontaneously.

3 months ago: she underwent modified radical mastectomy and received chemotherapy due to invasive ductal carcinoma of the left breast. Her oncologist referred the patient for dermatologic evaluation.

FHx : Nil

PE : Asymptomatic multiple discreted, well-circumcribed, oval, firm, skin - colored to reddish brown dermal papules, size 3-6 mm. in diameter located on lower lids, upper cheeks, neck, axillae, flexor aspect of upper arms and anterior chest.

Other physical examinations were unremarkable

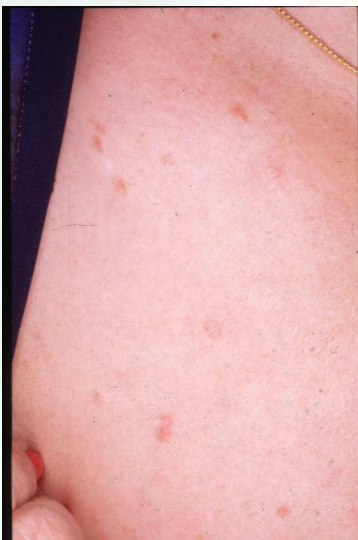

Fig. 15.1

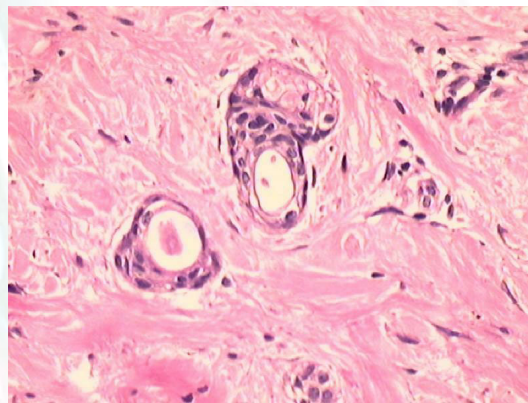


Fig. 15.2

Histopathology : Slide No. 41 - 0666 (trunk)

There are nests, cords and strands of cuboidal cells some of which show ductal differentiation in the upper dermis.

Diagnosis : Eruptive syringoma

Management : Carbondioxide laser vaporization.

Presenter : Siranya Silapunt, M.D.

consultant : Natta Rajatanavin, M.D.

Interhospital Dermatology Conference

References :

1. Biolcati G, Donati P. Eruptive syringoma. *J Am Acad Dermatol* 1993; 28 : 800-1.
2. Lee AY, Kawashima M, Nakagawa H., Ishibashi Y. Generalized eruptive syringoma. *J Am Acad Dermatol* 1991; 25 : 570-1
3. Janniger CK, Brodtkin RH. Eruptive syringoma. *Cutis* 1990; 46 : 247-249
4. Parker RK, Raque CJ. Eruptive syringoma. *Pediatric Dermatol* 1993; 10 : 91
5. Maroon M, Tyler W, Victor J. Calcinosis cutis associated with Syringoma : a transepidermal elimination disorder in a patient with Down syndrome. *J Am Acad Dermatol* 1990; 23 : 372-375.

Rama

Aug

