

Interhospital Dermatology Conference

Case 7

A 47 years old Thai female.

C/C Hyperpigmented patch at dorsum of right hand for 2 months.

P/I: Two months before, she noticed that she had hyperpigmented patch at dorsum of right hand. It was asymptomatic and no progression. It became darker in color during exposure to the sun.

Neither perfume nor lotion were applied., No history of chemical contact.

Dimetapp and Flemex were taken off and on for one year.

P/E An asymptomatic brown to grayish, ill defined patch without scale size 4 cm. in diameter at dorsal surface of right hand.

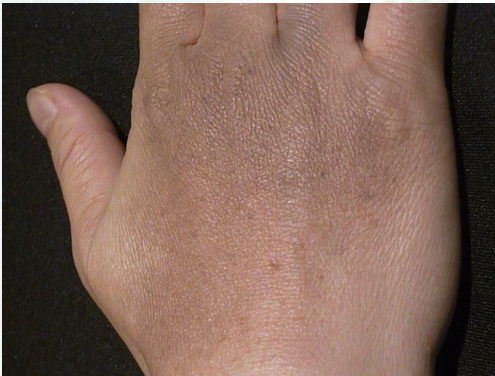

Fig. 7.1

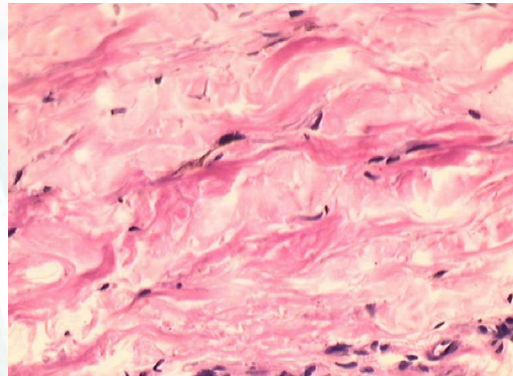


Fig. 7.2

Histopathology Slide no. 41-1100

Proliferation of dendritic melanocyte and with abundant melanin in upper dermis.

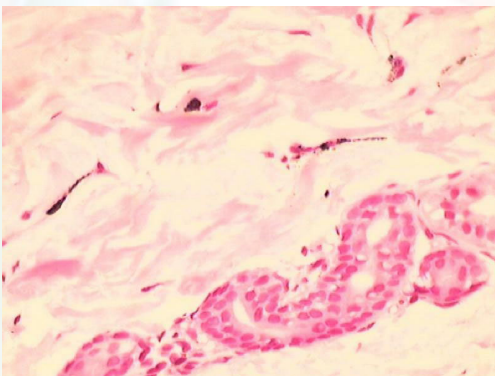


Fig. 7.3 Masson-Fontana stain

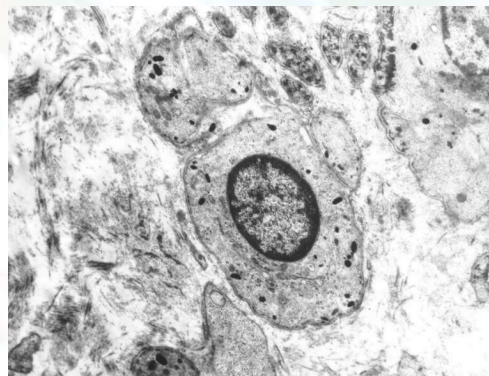


Fig. 7.4 EM (X 7000)

Interhospital Dermatology Conference

Diagnosis: Acquired Dermal melanocytosis

Treatment Q-Switched Nd:YAG laser.

Presenter Kanokwon Kanchanavijaya M.D.

consultant Siripen Puavilai, M.D.

References

1. Balloy-BC; Mallet-V; Bassile-G; Dubertret-L; Aractingi-S. Disseminated blue nevus: Abnormal nevoblast migration on proliferation Arch-Dermatol. 1998 Feb; 134(2) : 245-6.
2. Wen-Sy : plaque-type blue nevus. Review and an unusual ease. Acta-Derm-Venerol. 1997 Nov; 77(6) : 458-9.
3. Esther Jimenez, MD,a Pilar Valle, MD,a Cristina Villegas, MD,a Elia Roo, MD,a Evaristo Sanchez Yus, MD,a and Vicente Furio, MDb Madrid, Spain Unusual acquired dermal melanocytosis. Journal of the American Academy of Dermatology February 1994 Volume 30, Number 2, Part 1 : 277-278.
4. Ignazio Stangameli, MD; Paolo Bauer, MD; Lauro Bucchi, MD; Monica Serafini, PhD; Paolo Cristofolini, MD; Silvia Rafomelli, MD; Mario Cristofolini, MD: Critical effects of intense sun exposure on the Expression of Epiluminescence microscopy Features of Acquired melanocytic nevi.