

Interhospital Dermatology Conference

Case 6

A 53 year old female from Bangkok

C/C : Multiple subcutaneous nodules on face for 4 months

P/I : She presented with asymptomatic multiple subcutaneous nodules on her face that had developed over the past 4 months. The lesion slowly enlarged for 2 weeks.

PHx : She was injected with some substance on her face for 10 years.

She has diabetes mellitus , on glibenamide for 10 years.

No history of drug allergy.

P/E : Multiple discrete ,skin color subcutaneous nodules on face diameter about 1-2 cms ,firm consistency ,can not movable

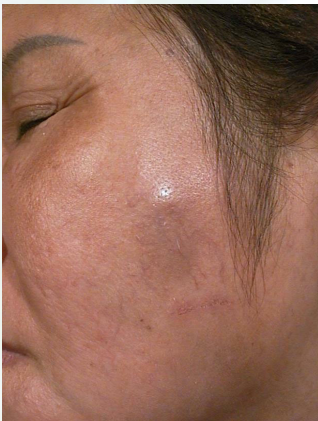

Fig. 6.1

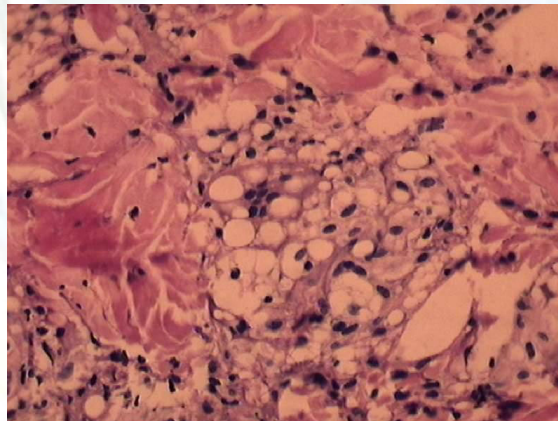


Fig. 6.2

Histopathology : Slide no. 41-1444

Diffuse infiltration of foamy histiocyte containing. Most histiocytes containing numerous multilocular vacuoles. Various sized vacuoles. Larged, variously sized clear spaces like "Swiss-cheese" appearance.

Investigation : Not done

Diagnosis : Siliconoma

Treatment : Supportive

Presenter : Wisuttida Taechotirote ,M.D.

consultant : Siripen Pauvilai ,M.D.

References :

1. Mason J, Apisarnthanarax P. migratory silicone granuloma. Arch Dermatol 1981; 117 : 366.

Interhospital Dermatology Conference

2. Morgan AW. Localized reactions to injected therapeutic materials: Part 2. J Cutan Pathol 1995; 22 : 289.

Ramathibodi Hospital

August 14, 1998

