

# Interhospital Dermatology Conference

## Case 4

A three-year-old girl from Bangkok.

C/C Asymptomatic yellowish brown papules on trunk for 2 years.

PHx Two years ago, her mother noticed groups of reddish brown macules and papules on her trunk. These lesions progressed to involve upper extremity

no other abnormal symptom

no familial history

PE A Thai girl looked healthy

HEENT ,Heart , Lung normal

Skin Discrete yellowish brown papules on trunk and extremities.

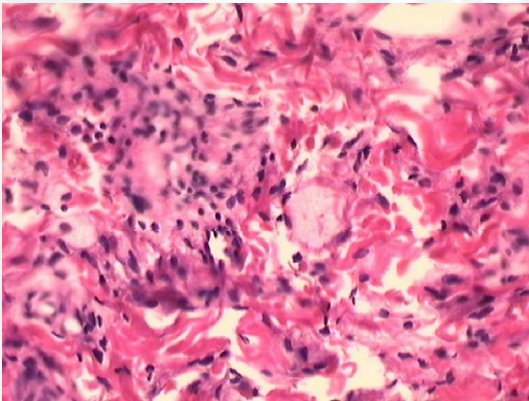


Fig. 4.1

### **Investigation :**

CBC WNL

LFT WNL

Cholesterol, Triglyceride WNL

CXR normal study

### **Histopathology :** slide no. 40-2901

Diffuse infiltrate composed mainly of histiocytes, but also foamy cell, giant cell and lymphocytes in the upper dermis.

**Diagnosis:** Juvenile xanthogranuloma

**Presenter** Somnuk Kamtavee, M.D.

# Interhospital Dermatology Conference

Consultant Siripen Puavilai, M.D.

## References

Ramathibodi Hospital

August

1. Ruggiero Caputo. Cutaneous Nonhistiocytoses X. In : Fitzpatrick TB, Eisen AZ, Wolff K, Freedberg IM, Austen KF, eds, Dermatology in general medicine 4<sup>th</sup> ed. New York : McGraw-Hill, 1993 ; 1261-69.
2. Walter H. C. Burgdorf. The Histiocytosis. In : David Elder., Lever's Histopathology of the skin 8<sup>th</sup> ed. 1997 ; 591-614.
3. Angela Hernandez-Martin, M.D. Juvenile Xanthogranuloma. J Am Acad Dermatol 1997; 36 : 355-65.
4. Zelger BG, Zelger B, Steiner H, et al. Solitary giant xanthogranuloma an benign cephalic histiocytosis :variants of juvenile xanthogranuloma. Br J Dermatol 1995; 133 : 598-604.

