

Interhospital Dermatology Conference

Case 3

A 23-year-old Thai man

CC Asymptomatic erythematous nodules and papules at Lt. axilla and face for 3 months.

PI He had been well till 4 years before. He presented with erythematous nodules on suprasternal area. The lesions disappeared in 6 months without treatment. He was diagnosed as eosinophilic granuloma by skin biopsy. The nodules recurred again with the same diagnosis by biopsy. He was treated by local radiotherapy 3 years ago. One year ago he had nodules again in the suboccipital and left axillary areas. Biopsy was done and followed by local radiotherapy.

3 months before visiting there were erythematous nodules and papules at the left axilla and face. Biopsy and radiotherapy were performed. He never had any bony or visceral organ involvement.

PE A healthy looking Thai man, afebrile, not pale no jaundice

Heart and lungs :- normal

Abdomen :- soft, not tender, Liver and spleen not palpate

Skin : groups of erythematous indurated papules, nodules, and plaque, on left axilla and discrete various sized erythematous small papules on face.

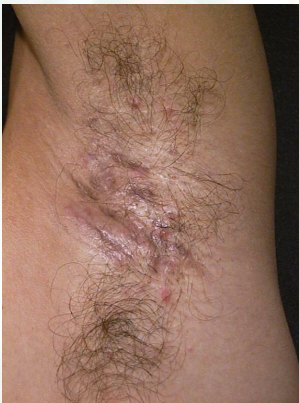

Fig 3.1

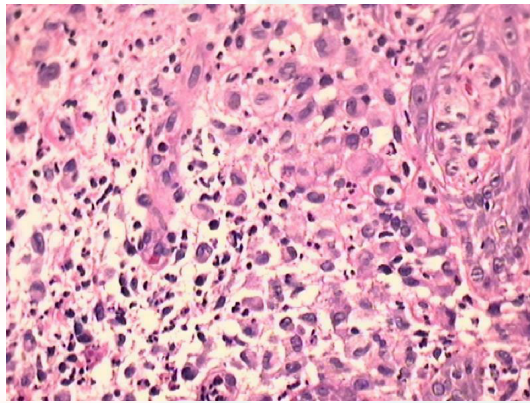


Fig 3.2

Investigation :

CBC : Hb 14.2 g/dL, Hct 42%, WBC 8600 N 72%, L23%, M4%, E1%, Plt 278,000

LFT : normal Coagulogram : normal

CXR : normal study Film skull : no lytic lesion

Histopathology

There are diffuse infiltrate of atypical histiocyte with eccentric kidney shaped nuclei intermingled with lymphocyte, neutrophils, and eosinophils in dermis.

Interhospital Dermatology Conference

Immunohistochemical study : CD1 positive

Diagnosis : Langerhans cell histiocytosis

Presenter Somnuk Kamtavee

Consultant Siripen Puavilai, M.D.

References:

1. Helmut Gadner, Nicole Grois. The histiocytosis Syndrome : In Fitzpatrick TB, Eisen AZ, Wolff K, Freedberg IM, Austen KF, eds. Dermatology in general medicine 4th ed. New York : McGraw-Hill, 1993 ; 2003-17.
2. Walter H.C. Burgdorf. The Histiocytosis. In : David Elder., Lever's Histopathology of the skin 8th ed. 1997 ; 591-614.
3. Watson-LC; Mendelsohn-SS; Nash-J. Adult-onset Langerhans cell histiocytosis associated with severe abscesses. Clin-Exp-Dermatol. 1995 Sep ; 20(5) : 415-8.
4. Mejia-R; Dano-JA. Langerhans's cell histiocytosis in adults. J Am Acad Dermatol. 1997 Aug; 37 : 314-7.
5. Hoeffel-C; Hoeffel-JC. Unifocal Langerhans cell histiocytosis. Australas-Radiol. 1996 Aug; 40(3):369-70
6. Moschella SL. An update of the benign proliferative monocyte macrophage and dendritic cell disorders. J-dermatol. 1996 Nov; 23 (11): 805-15.