MRI interpretation of the foot

Waraporn S. Boonsaeng, M.D.

Department of Radiology, Thammasat University

Outlines

- Technique
- Forefoot
  - First MTP joint
  - Lesser MTP & metatarsalgia
    - Plantar plate injury
    - Intermetatarsal space (morton neuroma, intermetatarsal bursitis)
    - Pressure lesions: soft tissue callus, adventitial bursitis
- Midfoot
  - Lisfranc ligament complex
- Osseous structures: BME

Standard MRI sequences

- Often focusing on a specific portion of the foot: ankle/hindfoot, midfoot, or forefoot
- Sagittal, short axis (coronal ankle) and long axis (axial ankle) planes relative to metatarsals
- Sagittal and short axis images: plantar plates, sesamoid bones and flexor and extensor tendons; intermetatarsal structures (short axis)
- Long axis images: collateral ligaments, Lisfranc ligament complex

Foot protocol (3 Tesla)

Sequence#	1	2	3	4	5	6
Sequence	T1NFS	T2FS	STIR	Int PDFS	T1NFS	T1NFS
Plane	Short axis (cor)	Short axis (cor)	sagittal	Long axis (axial)	Long axis (axial)	sagittal
TR/TI (mc)	750	5000	7300/ 130	3500	750	750
TE (mc)	10	80	30	55	10	10
Slice thickness (mm)	3/30	3/30	3/30	3/30	3/30	3/30
FOV (cm)	Smallest possible (<12)	Smallest possible (<12)	Smallest possible (<12)	Smallest possible (<12)	Smallest possible (<12)	Smallest possible (<12)
Matrix	256 × 256	180 × 256	230 × 384	152 × 256	256 × 256	180 × 256
Contrast	No	No	No	No	No	No

Arnold G, et al. Magn Reson Imaging Clin N Am 19 (2011) 655–679

Suggested protocol for imaging the midfoot

	Coronal IR Inversion Time 150	Coronal PD	Axial PD	Sagittal PD
TR	4500	4500	4500	5000
TE	16	27	26	25
ST	3.0	2.0	3.0	4.0
ETL	12	14	18	14
FOV	160	150	110	160
Matrix	256 × 192	512 × 320	512 × 320	512 × 256
NEX	2	2	2	2

Coronal, parallel to the bottom of the foot; Axial, transverse to the longitudinal arch of the foot.

From approximately the mid subtalar joint to the proximal metatarsals

Sofka CM. Magn Reson Imaging Clin N Am 25 (2017) 1–10

Suggested protocol for imaging the forefoot

	Coronal IR Inversion Time 170	Coronal PD	Axial PD	Sagittal PD Lesser Toes	Sagittal PD Hallux
TR	6200	5500	6700	4100	6100
TE	18	25	25	25	25
ST	2.5	2.0	2.8	2.5	1.2
ETL	12	12	16	14	12
FOV	160	120	120	140	140
Matrix	256 × 192	512 × 384	512 × 384	512 × 384	512 × 256
NEX	1	1	1	1	1

Coronal, parallel to the bottom of the foot; Axial, Transverse to the longitudinal arch of the foot.

From approximately the naviculocuneiform articulation through the toes.

Sofka CM. Magn Reson Imaging Clin N Am 25 (2017) 1–10

Lesser MTP and Metatarsalgia

- Plantar plate
- Morton neuroma
- Intermetatarsal bursitis
- Soft tissue callus
- Adventitial bursitis

Plantar plate

- Primary stabilizer of the lesser MTP joints, especially in the dorsal–plantar direction
- Articulates directly with the plantar surface of the lesser metatarsal head
- A firm, flexible fibrocartilaginous structure that has a mean length of 20 mm and average thickness of 2 mm at the second MTP joint

Plantar plate anatomy

- Uniform dark signal deep to the metatarsal head
- Flexor digitorum tendon courses beneath and non-discernable intervening cleavage plane.
- Normal capsular recess, 47% in the midsagittal plane*

*Mohana-BorgesAVR,et al. Radiology 2003;227:175–82.

Plantar plate anatomy

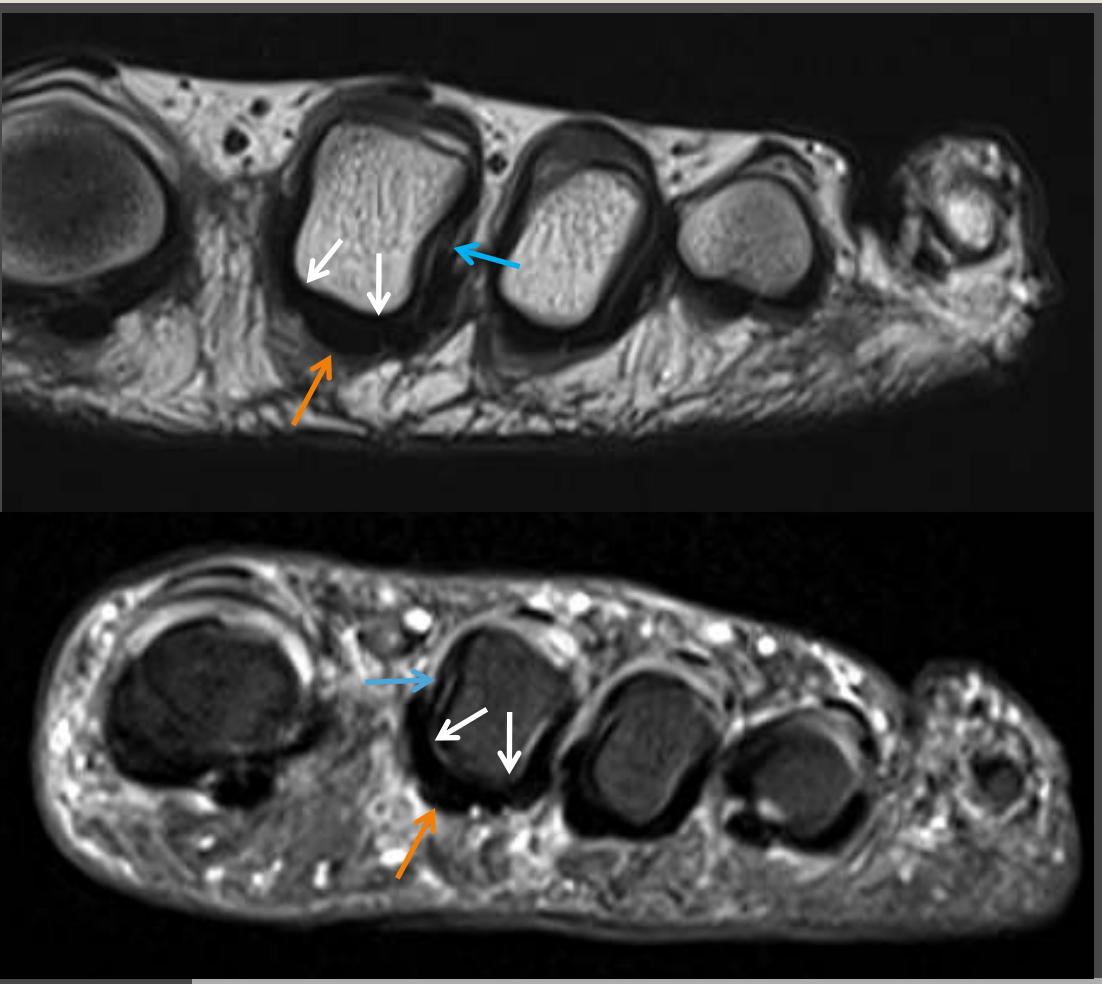

- Plantar plate: a thick c-shaped low signal band
- Central groove for flexor digitorum longus and brevis tendons
- Proper collateral ligaments blend with the plantar plate at base of proximal phalanx insertions.

Medial and lateral collateral ligaments

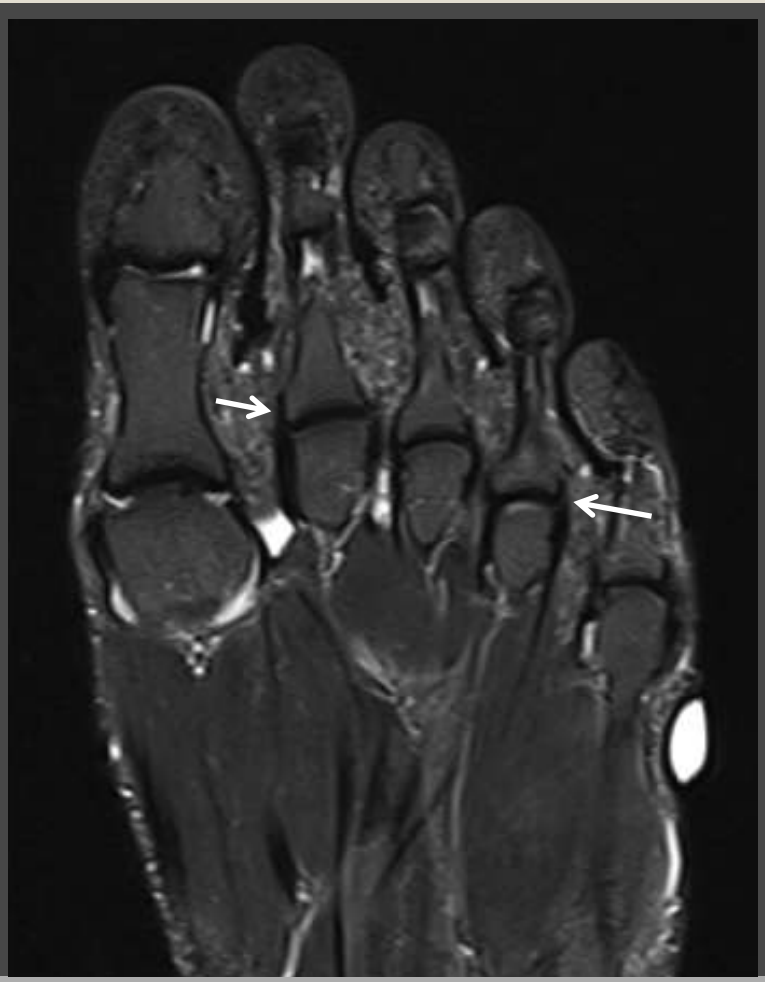

- Best for evaluating the attachment of collateral ligaments onto the bilateral base of the proximal phalanges
- Collateral ligaments have a close relationship with the interosseous, abductor digiti minimi, and flexor digiti minimi brevis tendons

Plantar plate injury

- Typically a chronic acquired degenerative condition
- Common at 2nd MTP
- Predisposing factors:
  - A long second metatarsal
  - Relative shortening of the first ray: cavus foot, mildly increased metatarsus adductus, a supinated foot, or a forefoot varus deformity (plantar flexed "shortened" position of the first ray)
- Plantar plate rupture: MC at the distal, lateral insertion onto the proximal phalangeal base

Second metatarsal protrusion

- > 4 mm, trend toward correlation with plantar plate tear*

*Umans R, et al. Radiological Society of North America 2014 Scientific Assembly and Annual Meeting. Chicago, IL, November 30-December 5, 2014.

The “crossover toe” end-stage disabling deformity

Image from Magn Reson Imaging Clin N Am 25 (2017) 127–144

Plantar plate tear

- Partial or complete discontinuity at the insertion
- Focal high T2W SI of the plantar plate

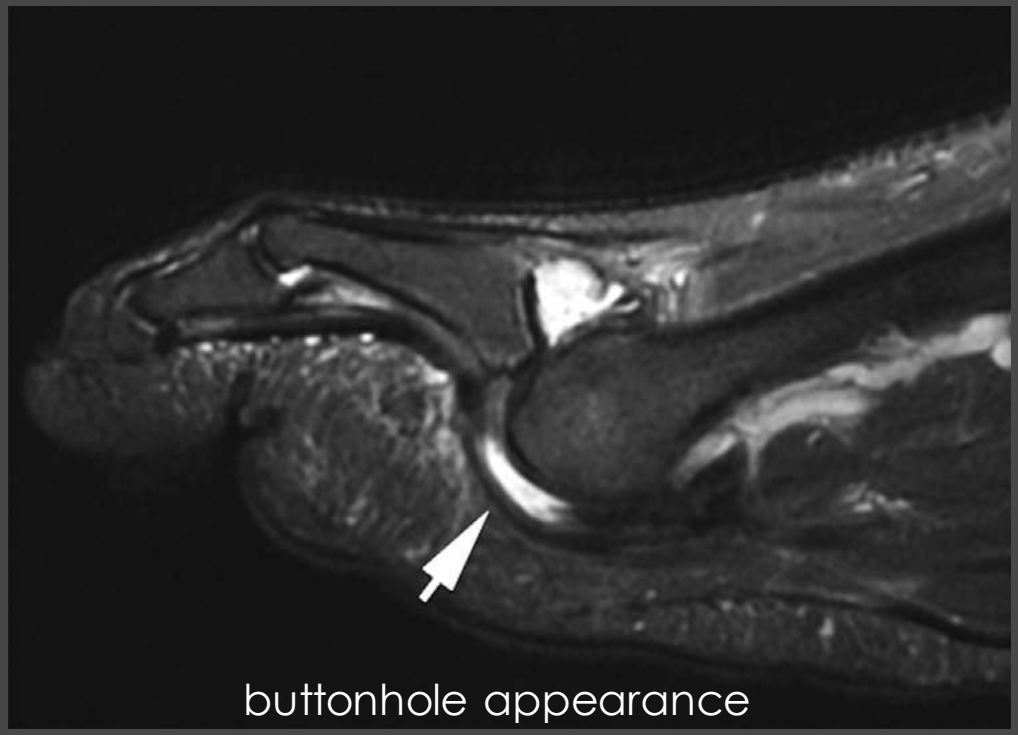

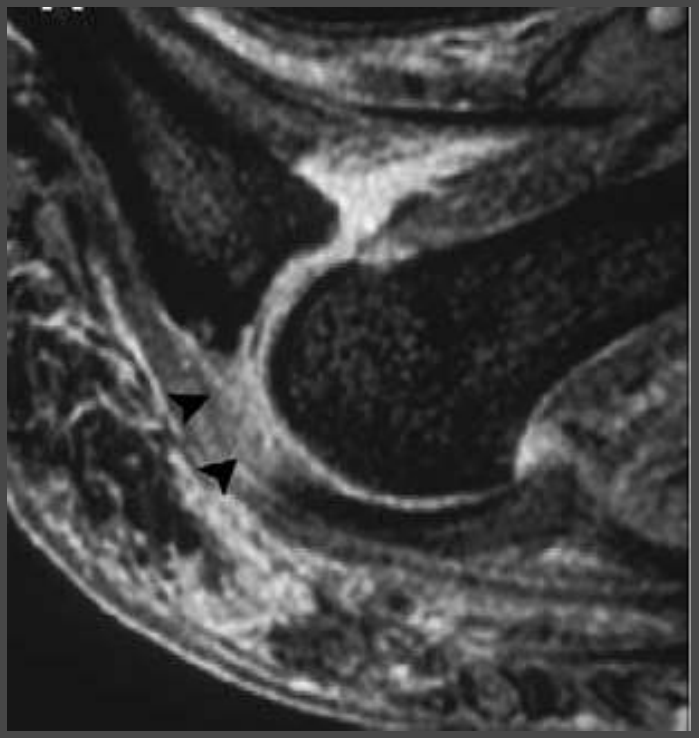

Nery C, et al. Magn Reson Imaging Clin N Am 25 (2017) 127–144

Clin Sports Med 25 (2006) 763–780

Plantar plate tear

- Thinning or non-visualization of the plantar plate
- Increased distance between the distal margin of plantar plate and the base of the proximal phalanx
- Distortion of the interosseous tendon and collateral ligament complex

Plantar plate tear

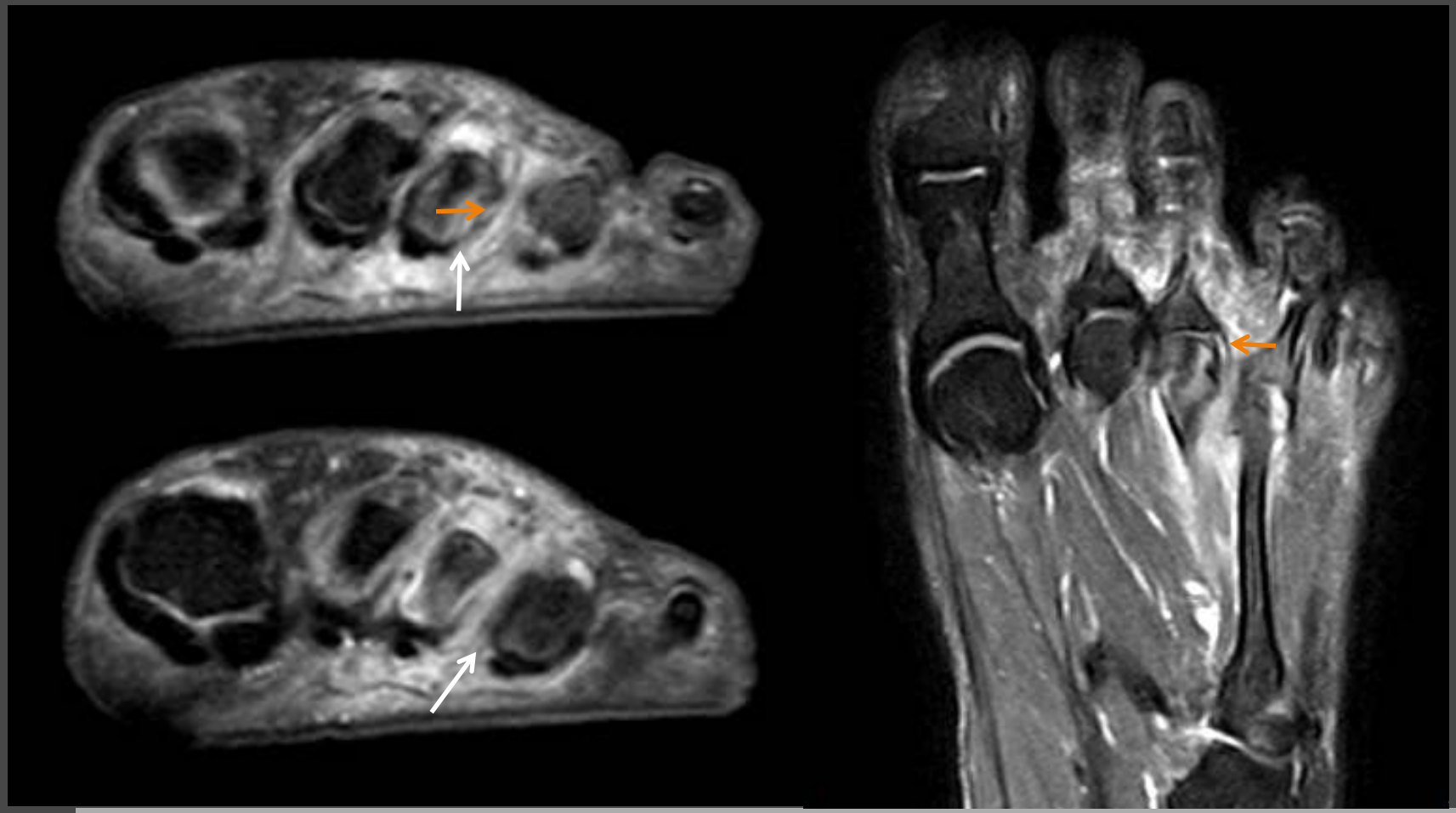

Morton neuroma

- Fibrosis and neural degeneration surrounding the plantar digital nerve
- More commonly in women, possibly a result of wearing higher heeled shoes
- Most likely due to repetitive compression and irritation of the nerve
- 2nd and 3rd intermetatarsal spaces, along plantar aspect of transverse intermetatarsal ligament

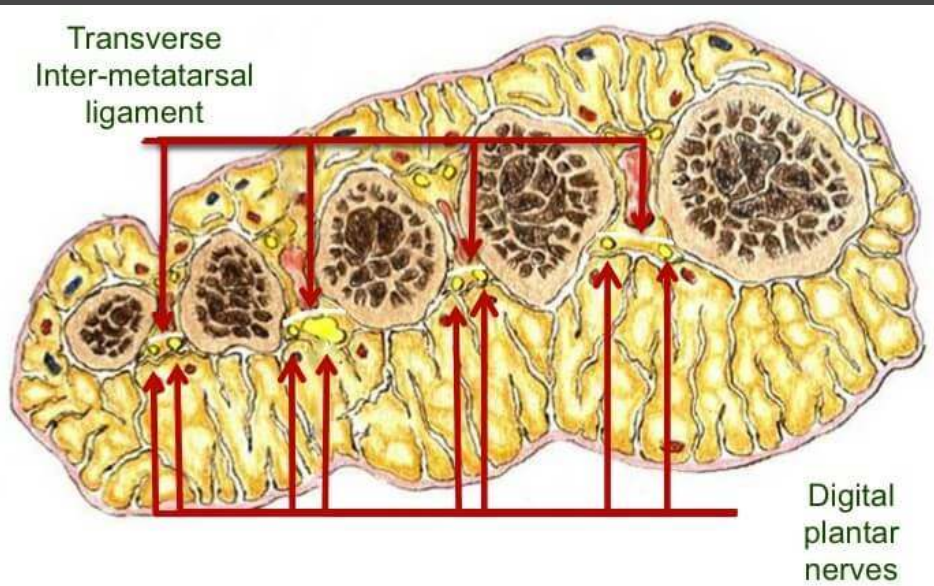

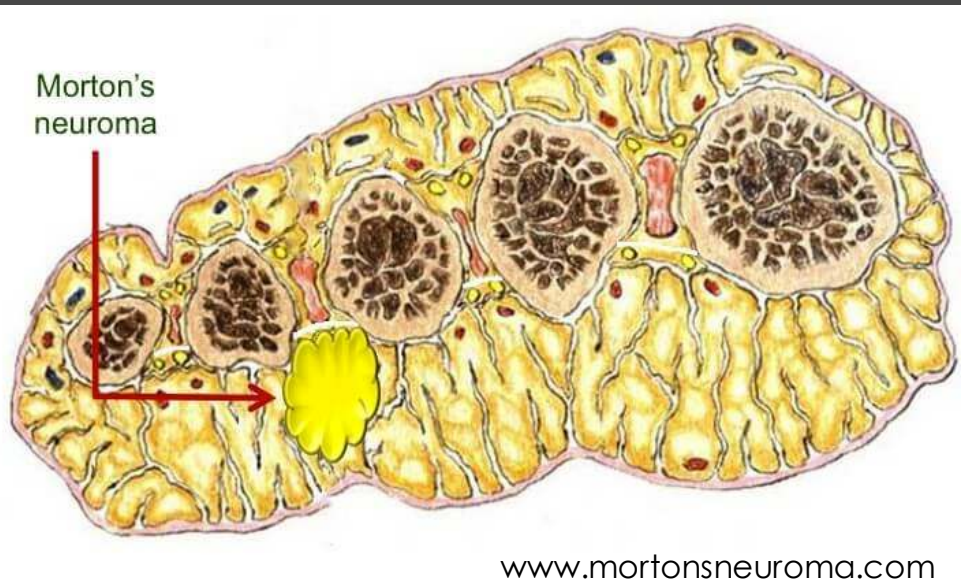

www.mortonsneuroma.com

Morton neuroma

- Rounded, or dumbbell-shaped masses between the metatarsal heads
- Isointense to muscle on T1W, hypointense relative to fat on T2W and varying enhancement

Morton neuroma

- Dumbbell-shaped masses between the metatarsal heads
- Isointense to muscle on T1W, hypointense relative to fat on T2W and varying enhancement

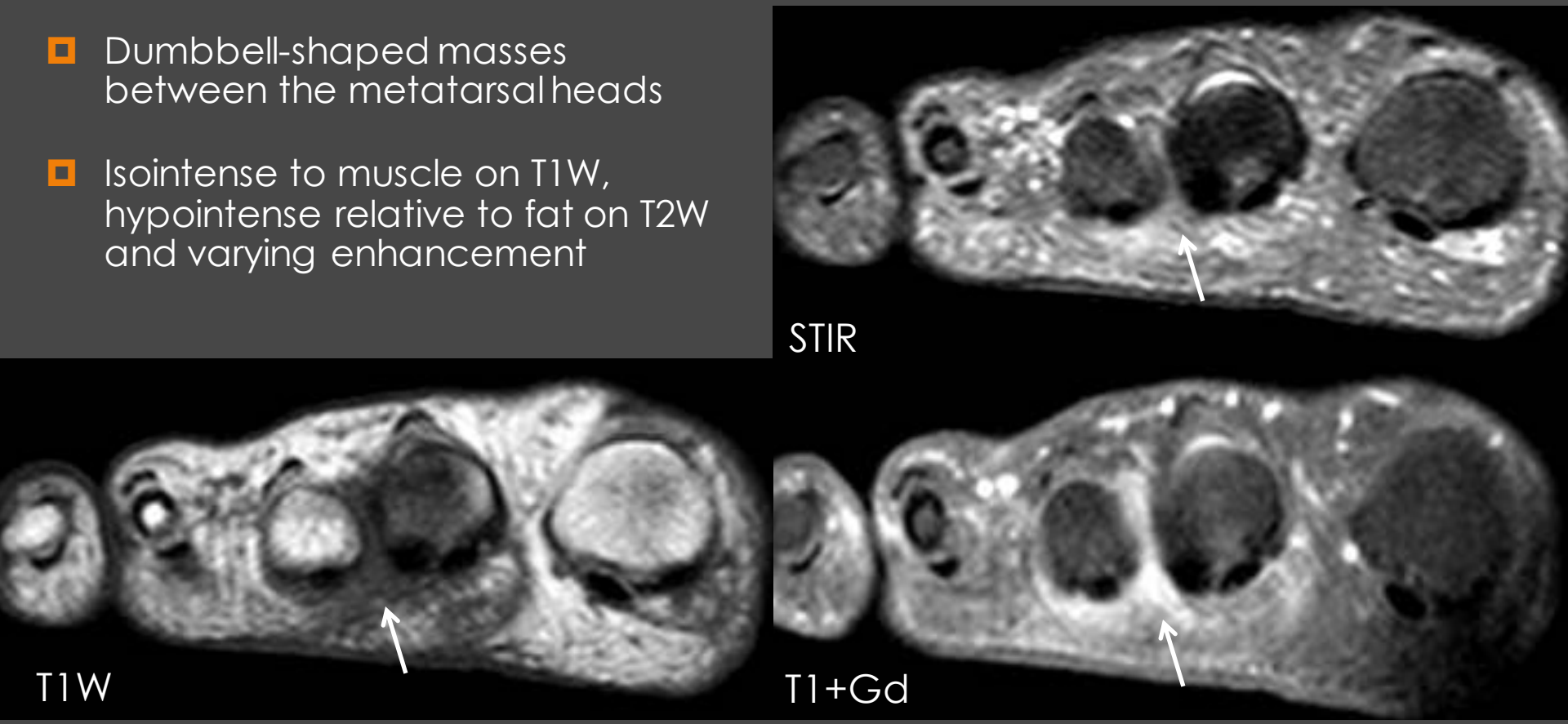

Intermetatarsal bursitis

- Homogeneous low T1/high T2 mass between metatarsal head, peripheral enhancement
- Extends dorsal to the level of intermetatarsal ligament, no plantar extension
- Small fluid collections with a transverse diameter ≤ 3 mm in the 1st three intermetatarsal bursae may be physiologic.

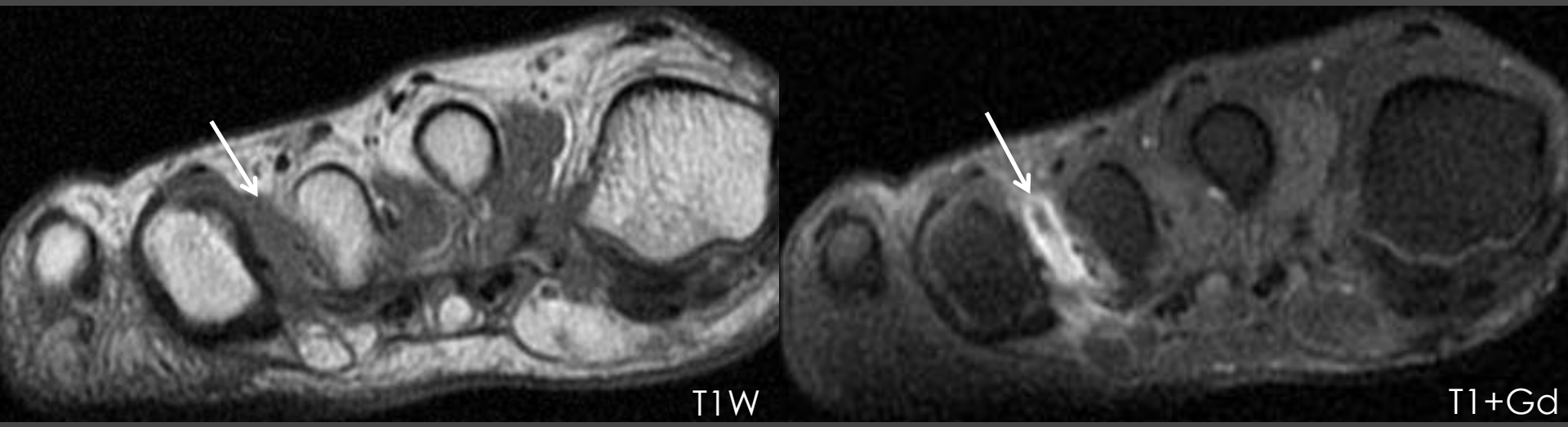

Pressure lesions - soft tissue callus

- Benign fibroblastic response to chronic mechanical pressure
- Focal masslike infiltration in superficial plantar subcutaneous fat
- Typically in forefoot (beneath the 1st&5th metatarsal heads and distal phalanx of the hallux) and heel; deep to the cuboid in rocker bottom deformities
- MRI: low signal compared with surrounding fat on T1W and T2W, enhances
- In DM, can become ulcerated and infected, and a conduit for deep infection

Soft tissue callus

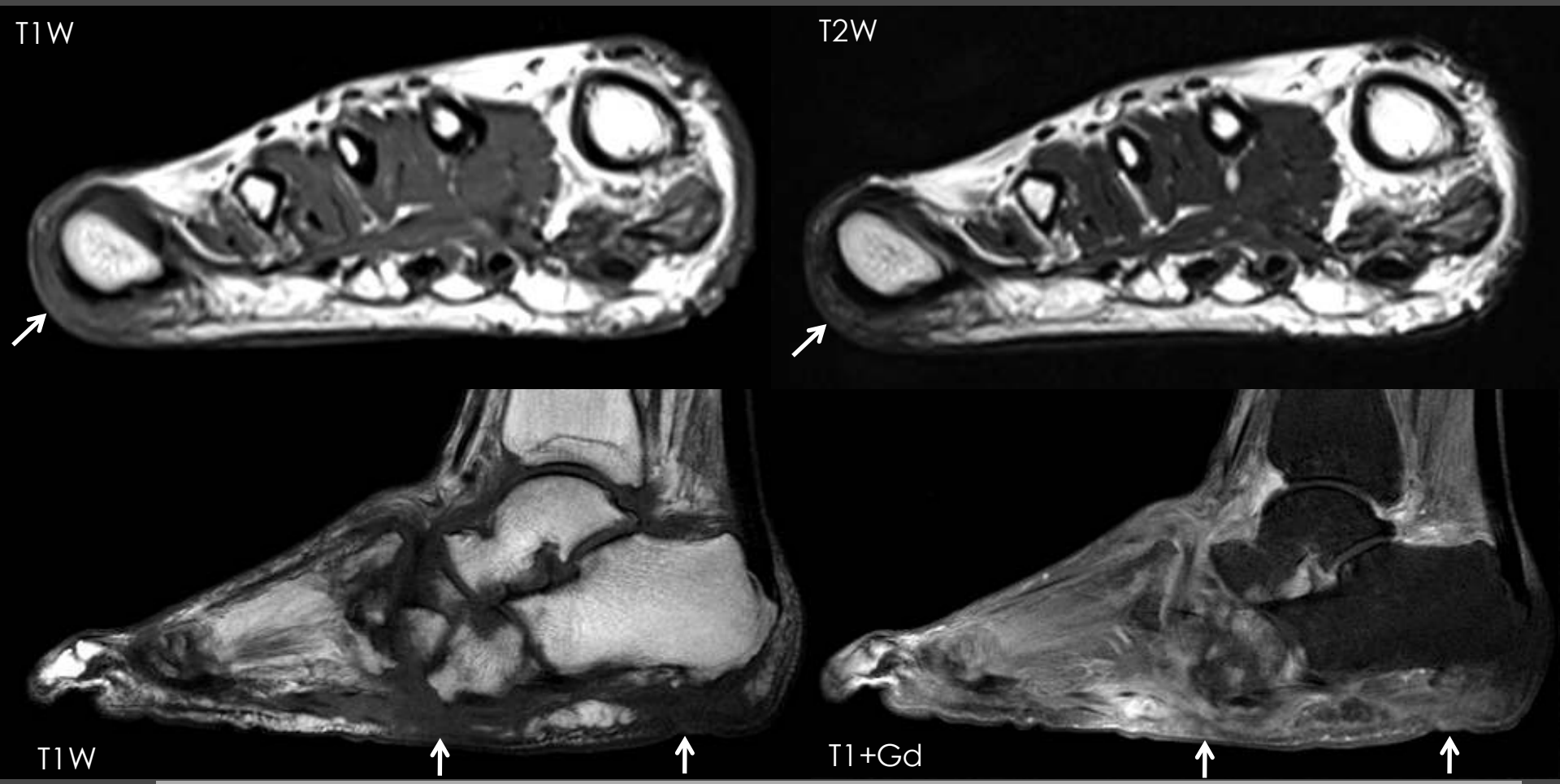

Adventitial bursitis

- Develop sporadically owing to increased friction
- Chronic friction at the callus can lead to overlying adventitial bursitis.
- May be asymptomatic or present as a painful mass (when inflamed)
- In the fat plantar to 1st metatarsal & plantar and lateral to 5th metatarsal head; retro-Achilles bursa; and malleolar bursae (medial > lateral)
- Inflamed bursae → fill with fluid and/or thickened synovium

Adventitial bursitis

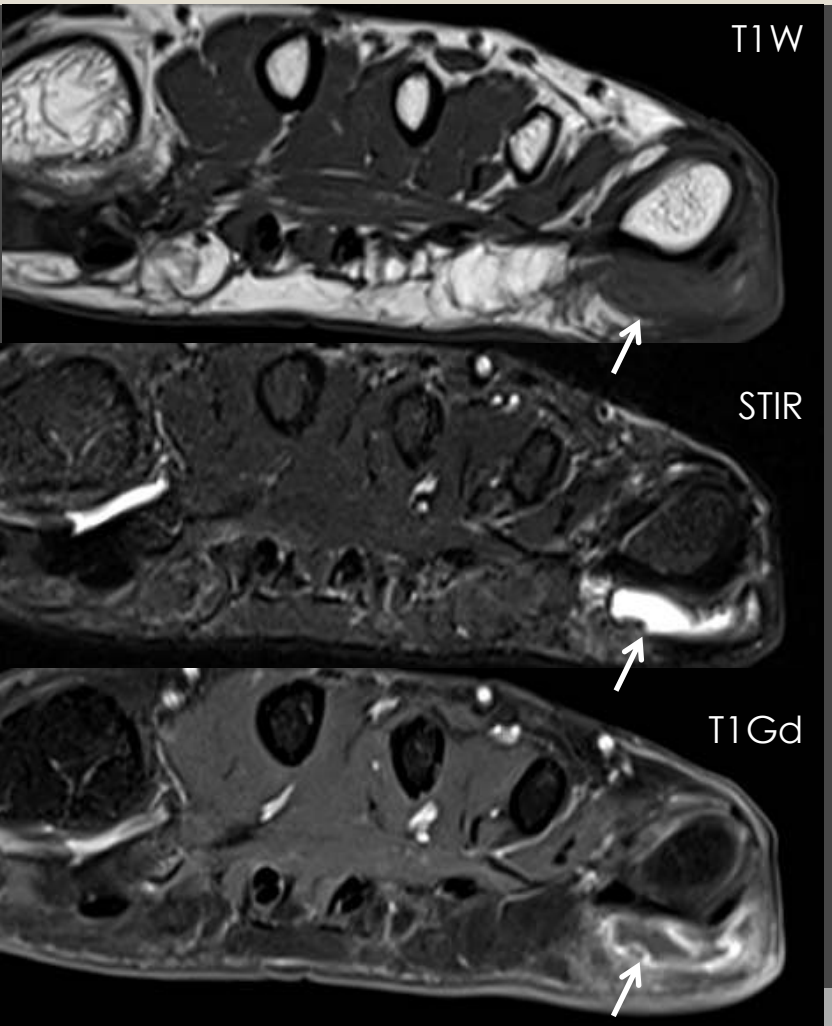

- Tend to have a pliable, discoid shape
- Iso- or slightly hyperintense to muscle on T1W, high SI on T2W, thin rim of enhancement
- Inflamed bursae: thickened, enhancing rim peripherally and more complex internal enhancement
- Fibrosis predominately: low T2 signal

Midfoot

- Lisfranc ligament complex

Lisfranc joint complex

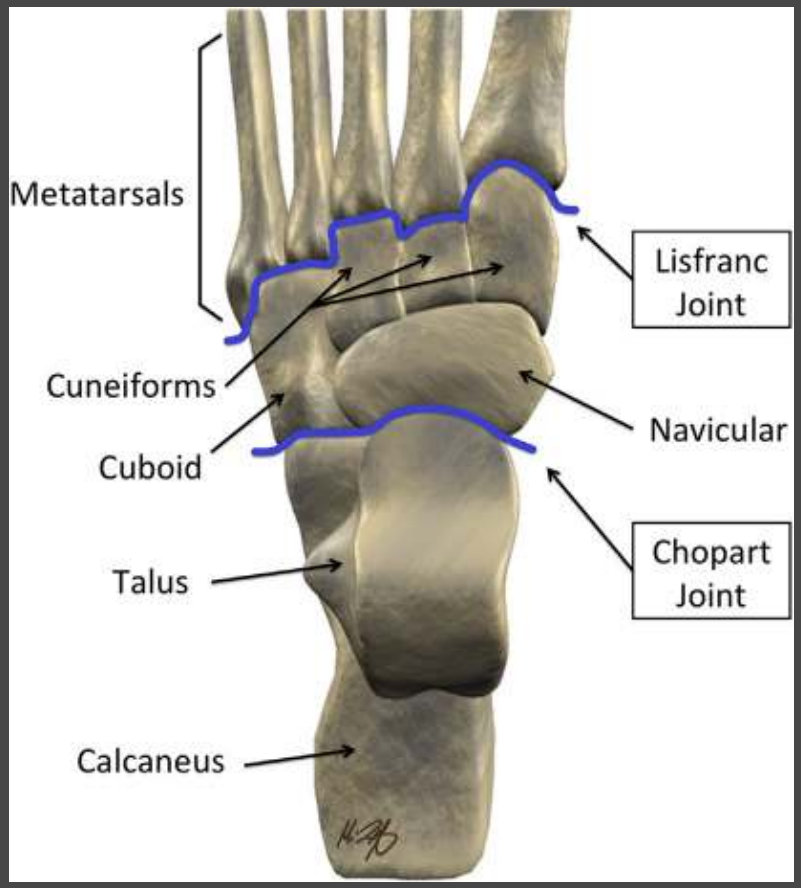

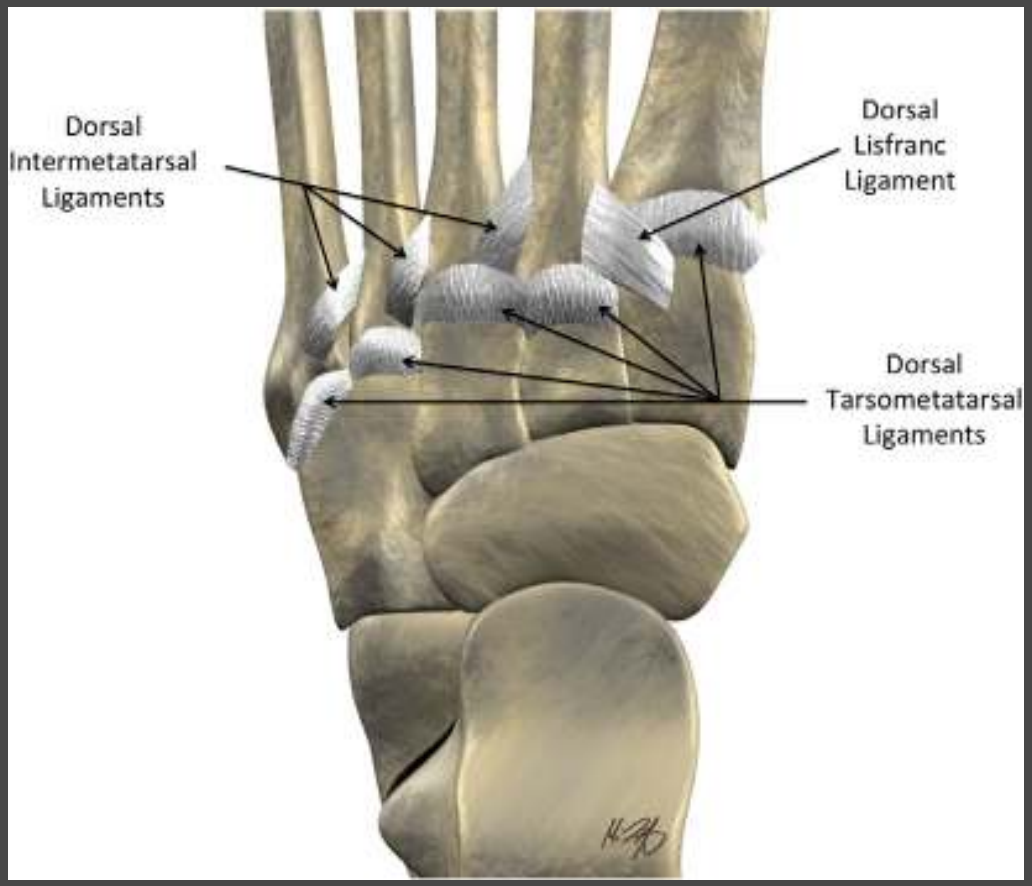

Tafur M, et al. Magn Reson Imaging Clin N Am 25 (2017) 95–125

Lisfranc ligament

- 3 parts
  - Interosseous Lisfranc ligament (strongest)
  - Dorsal component, weak

↓

Oblique ligaments extend from medial cuneiform to 2nd metatarsal base.

  - Plantar component: C1 to bases of M2 & M3

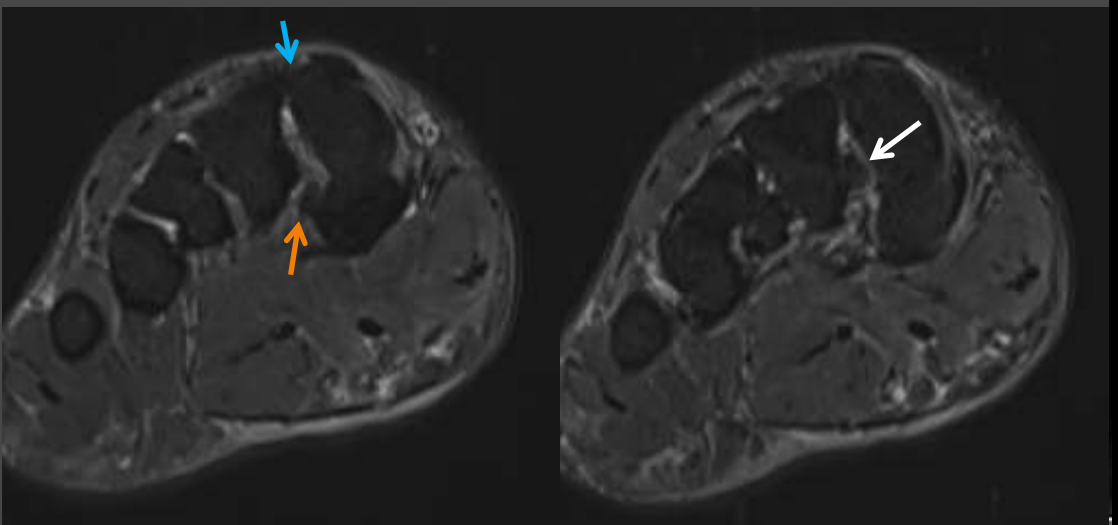

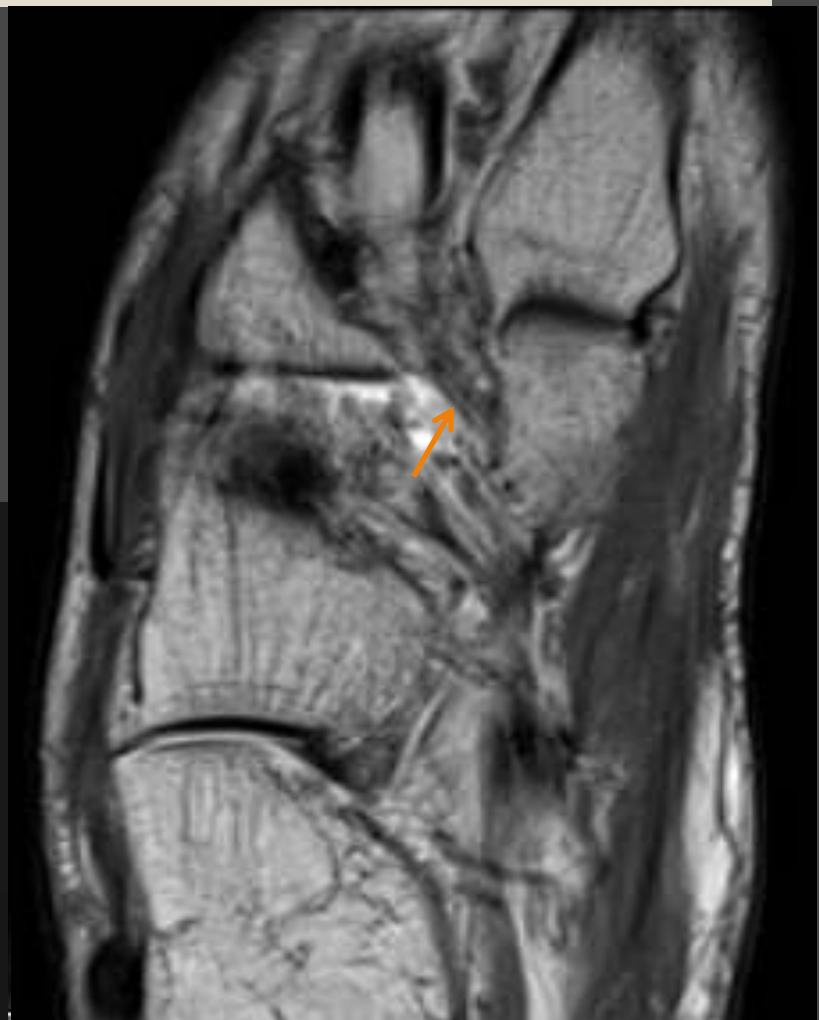

Lisfranc joint complex injury

- High-energy vs low-energy trauma
- Midfoot sprains
  - Sports-related and due to indirect forces
  - Nunley and Vertullo classification

Stage	Clinical findings	Radiographic findings*
I	Low-grade sprain and dorsal capsular tear with intact joint stability	Normal
II	Elongation or disruption of Lisfranc ligament with intact plantar capsular structures	AP: 2–5-mm M1-M2 diastasis Lateral: no loss of arch height
III	Loss of arch height and disruption of the interosseous and plantar Lisfranc ligaments	AP: >5-mm M1-M2 diastasis Lateral: decreased distance between the plantar surfaces of C1 and M5

*Anteroposterior, lateral, and 30° internally rotated oblique weight-bearing films

Lisfranc ligament injury

- Fluid surrounding the Lisfranc ligament
- Ligament irregularity or frank disruption
- Abnormal signal intensity within the ligament

Primary signs

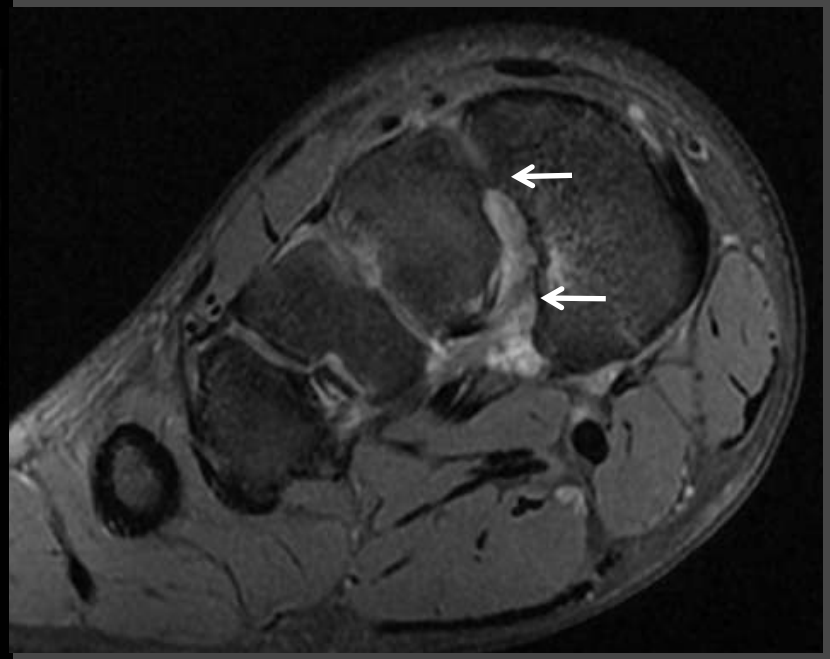

Images from http://radiologycases.blogspot.com

Lisfranc ligament injury

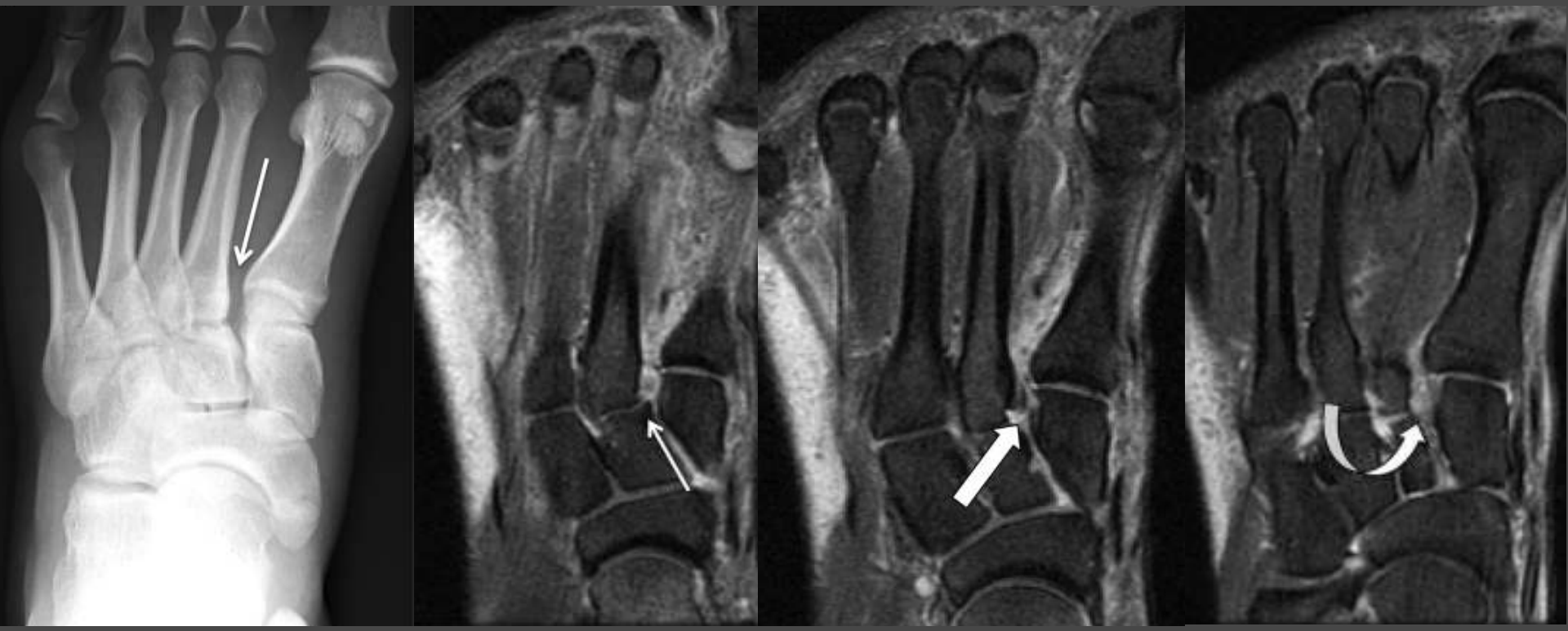

Tafur M, et al. Magn Reson Imaging Clin N Am 25 (2017) 95–125

Lisfranc ligament injury

Fleck-sign: small avulsion fractures at base of the M2 or C1

Lisfranc ligament injury

- Fractures along the 2nd cuneometatarsal joint
- Contusions at the tarsometatarsal joints
- Soft tissue edema surrounding the 2nd metatarsal
- Edema in the 1st dorsal interosseous muscle

Secondary signs

Tafur M, et al. Magn Reson Imaging Clin N Am 25 (2017) 95–125

Lisfranc ligament injury

- Thickening of the interosseous Lisfranc ligament, particularly in setting of tarsometatarsal osteoarthrosis → typically indicate old midfoot sprain.

Tafur M, et al. Magn Reson Imaging Clin N Am 25 (2017) 95–125

Bone marrow edema pattern

- Challenging in diabetic foot
  - Early osteomyelitis vs stress response/bone marrow reaction
  - Early neuropathic arthropathy vs infection
- Early osteomyelitis
  - Identify a site of direct inoculation (skin/soft tissue defect with a sinus tract or abscess extending to the bones)
  - Focal or diffuse replacement of normal marrow fat on T1W → most reliable
  - Frank cortical destruction and/or periosteal reaction
  - Geographic enhancement on T1 post contrast

DM with direct osteomyelitis from ulcer

Bone marrow response to surrounding soft tissue infection

Bone marrow edema patterns

Early neuropathic arthropathy

- Diffuse soft tissue and bone marrow edema with increased enhancement
- Common at Lisfranc, Chopart or MTP joints
- Multiple bone and joint involvements
- Joint centered, and tend to occur symmetrically on either side of the joint

Early osteomyelitis

- Site of direct inoculation
- Occur distal to TMT joint, and in malleoli and calcaneus
- Single bone involvement
- Tend to be limited to one side of a joint (in absence of septic arthritis)

Neuropathic arthropathy-DM

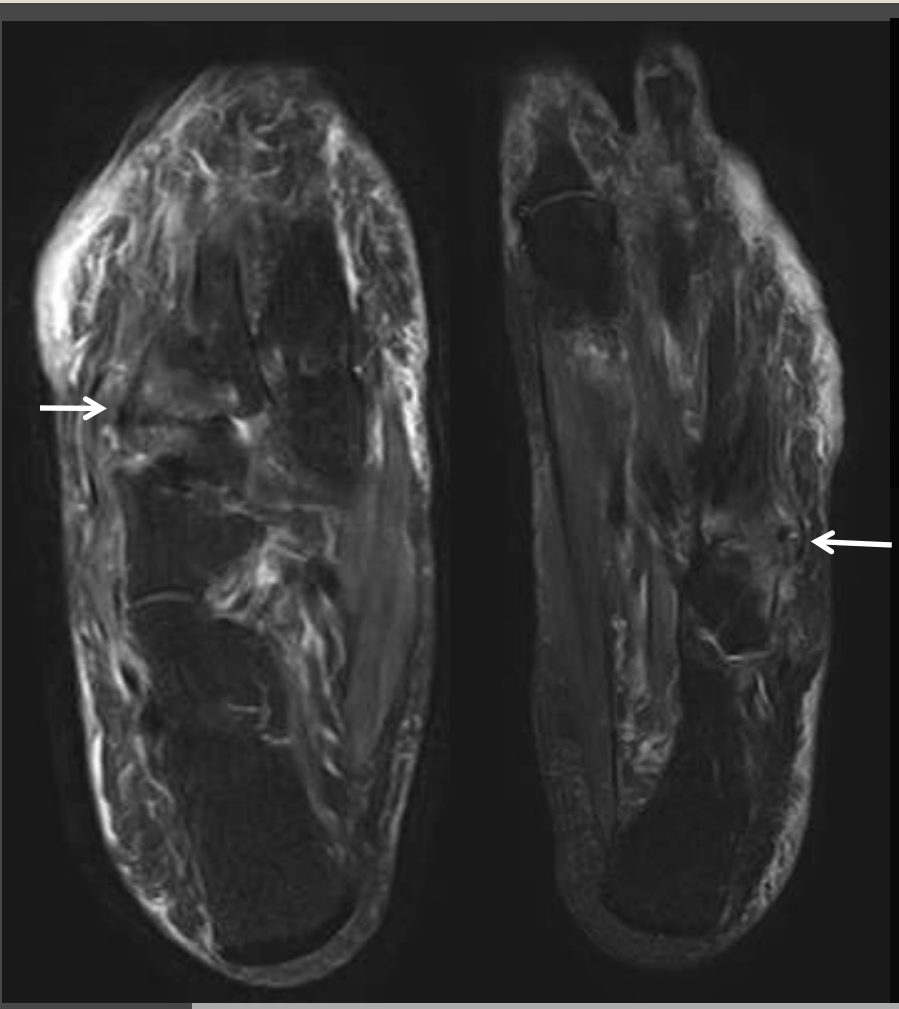

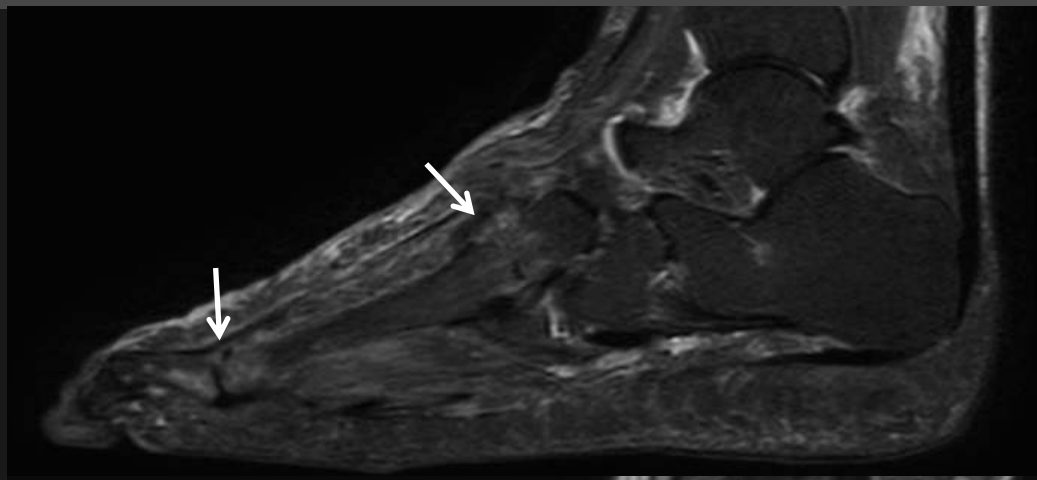

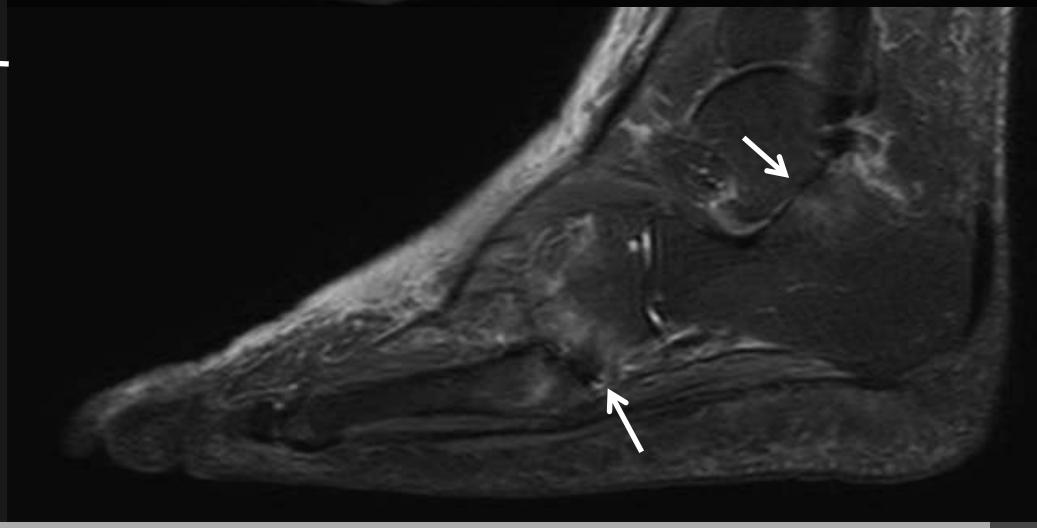

Reference

- Sofka CM. Technical Considerations Best Practices for MR Imaging of the Foot and Ankle. Magn Reson Imaging Clin N Am 2017 Feb;25(1):1-10.
- Nery C, Baumfeld D, Umans H, Yamada AF. MR Imaging of the Plantar Plate: Normal Anatomy, Turf Toe, and Other Injuries. Magn Reson Imaging Clin N Am 2017 Feb;25(1):127-144.
- Hochman MG, Wu JS. MR Imaging of Common Soft Tissue Masses in the Foot and Ankle. Magn Reson Imaging Clin N Am 2017 Feb;25(1):159-181.
- Siddiqui NA, Galizia MS, Almusa E, et al. Evaluation of the tarsometatarsal joint using conventional radiography, CT, and MR imaging. Radiographics 2014; 34: 514–531.
- Tafur M, Rosenberg ZS, Bencardino JT. MR Imaging of the Midfoot Including Chopart and Lisfranc Joint Complexes. Magn Reson Imaging Clin N Am 2017 Feb;25(1):95-125.
- McCarthy E, Morrison WB, Zoga AC. MR Imaging of the Diabetic Foot. Magn Reson Imaging Clin N Am. 2017 Feb;25(1):183-194.
- Arnold G, et al. Normal Magnetic Resonance Imaging Anatomy of the Ankle & Foot. Magn Reson Imaging Clin N Am 2011; 19:655–679.
- Umans HR. Imaging sports medicine Injuries of the foot and toes. Clin Sports Med 2006; 25:763-780.
- Linklater JM. Imaging of sports injuries in the foot. *AJR 2012; 199:500–508.*
- Ashman CJ, Klecker RJ, Yu JS. Forefoot pain involving the metatarsal region: differential diagnosis with MR imaging. RadioGraphics 2001;21:1425–1440.