Musculoskeletal Infection Extremities

Nuttaya Pattamapaspong M.D.
Department of Radiology, Faculty of Medicine, Chiang Mai University, Chiang Mai, Thailand

Topics

- Role of imaging in extremity infection
- Pathophysiology
- Imaging features

Role of Imaging in Extremity Infection

- Detection of infection
- Determination the disease extent
- Guidance for intervention procedure

Detection of Infection

Challenges

- Musculoskeletal infections have multiple patterns of presentation.
- Variability of the host immune response and virulence of pathogen.
- Clinical presentation & radiological features may similar to those of non-infectious process.
- 50% of children having musculoskeletal infection are misdiagnosed as tumors or other conditions.*

* Rasool MN, JBJS(Br) 2001

Detection of Infection

Challenges

- Increased immunocompromised patients (AIDs, chemotherapy, steroid, immunosupressive drugs)
- If untreated, musculoskeletal infection leads to fatal outcome or amputation.
- Infectious diseases are common problems of the tropical region.

Anatomy & infection

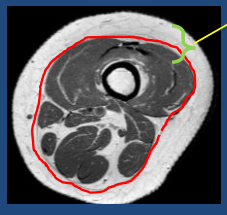

- Superficial soft tissue infection
  - Skin
  - Subcutaneous tissue
  - Superficial fascia

(Cellulitis)

Anatomy & infection

- Deep soft tissue infection
  - Deep/inter-compartment fascia (fasciitis)
  - Muscle (pyomyositis)
  - Bursitis/tenosynovitis
  - Arthritis
  - Osteomyelitis

Detection of Infection

Imaging of choices

- Radiographs
- CT
- US
- MRI

Detection of Infection: Radiographs

- Osseous lesions:

Bone destruction, periosteal reaction, osteosclerosis, sequestra, involucrum

- Radio-opaque foreign bodies
- Soft tissue gas

A 54 yo man post traumatic chronic osteomyelitis

Detection of Infection: Radiographs

- Osseous lesions:

Bone destruction, periosteal reaction, osteosclerosis, sequestra involucrum

- Radio-opaque foreign bodies
- Soft tissue gas

- Radio opaque Metal foreign bodies

Detection of Infection: Radiographs

- Gas/ necrotizing fasciitis

- Osseous lesions:

Bone destruction, periosteal reaction, osteosclerosis, sequestra involucrum

- Radio-opaque foreign bodies
- Soft tissue gas

Detection of Infection: CT

- Improve detection comparing to radiographs
- Osseous lesions:

Bone destruction, periosteal reaction, osteosclerosis, sequestra

- Soft tissue gas, abscesses
- Foreign bodies

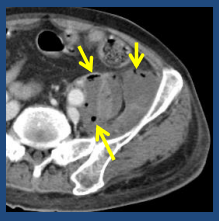

Left iliopsoas abscesses with gas bubbles

Detection of Infection: CT

- Improve detection comparing to radiographs
- Osseous lesions:

Bone destruction, periosteal reaction, osteosclerosis, sequestra

- Soft tissue gas, abscesses
- Radio-opaque foreign bodies

A 65 yo man with retained pieces of glass for 20 years

Detection of Infection: CT

- Improve detection comparing to radiographs
- Osseous lesions:

Bone destruction, periosteal reaction, osteosclerosis, sequestra

- Soft tissue gas, abscesses
- Radio-opaque foreign bodies

Wooden foreign body

Swelling of the foot for 2 wks
History of penetrating injury last 5 years.

Detection of Infection: US

- Distinguish superficial/ deep soft tissue infection.
- Soft tissue abscesses
- Foreign bodies
- Joint effusion
- Subperiosteal abscess/ cortical bone destruction

Wooden foreign body

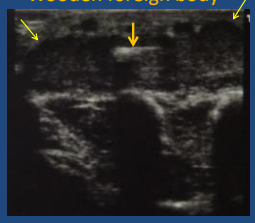

Penetrating injury with abscess in the dorsum of hand

Detection of Infection: US

- Distinguish superficial/ deep soft tissue infection.
- Soft tissue abscesses
- Joint effusion
- Subperiosteal abscess/ cortical bone destruction

Thrombophlebitis

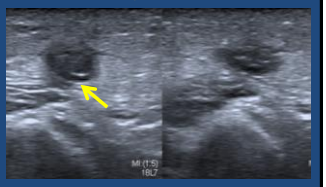

compressed

Detection of Infection & Guide of Treatment

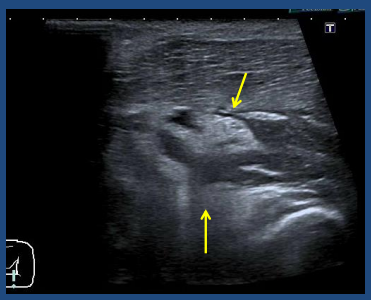

Abscess, real time scan

Detection of Infection: US

- Distinguish superficial/ deep soft tissue infection.
- Soft tissue abscesses
- Joint effusion
- Subperiosteal abscess/ cortical bone destruction
- Foreign bodies
- Guide of aspiration

Post surgical infection

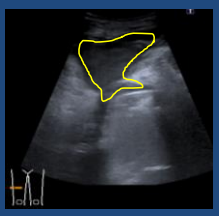

Detection of Infection: US

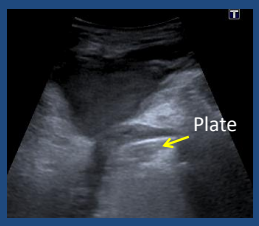

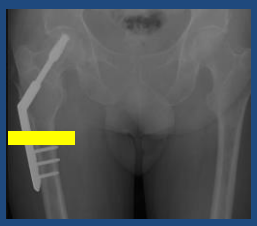

Transverse US of the thigh

Underlying multiple myeloma with post operative thigh pain and fever

Detection of Infection: US

- Distinguish superficial/ deep soft tissue infection.
- Soft tissue abscesses
- Joint effusion
- Subperiosteal abscess/ cortical bone destruction
- Foreign bodies
- Guide of aspiration
- Cortical bone destruction of the femur

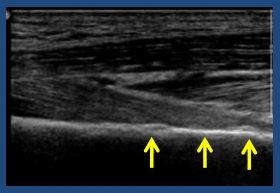

Longitudinal scan of the thigh

US

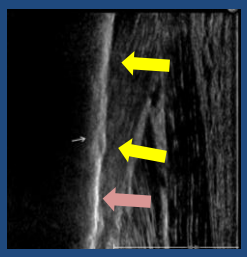

T1 fat sat+Gd

Pathophysiology & Imaging Features

Sources of infection
- Hematogenous spread
- Contiguous infection
- Penetrating injury

↓

Skin, Subcutaneous tissue, Muscles, Joints, Bursa, Tendon sheaths, Bones

Inflammatory response and tissue damage

↓

Abscess formation
Surrounding tissue reaction & reparative process

Imaging Features : Hematogenous spread infection

Single lesion in high vascular area

A 4 yo boy acute osteomyelitis in the metaphysis

Multiple lesions

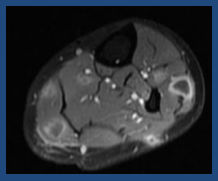

A 24 yo/F, leukemia, disseminated fungal infection (*Fusarium spp.)*

Imaging Features Contiguous infection

- A 72-year-old woman
- Shoulder pain with a mass for 1 year.
- Tuberculous arthritis with subacromion subdeltoid bursitis

Shoulder coronal T1 +Gd

Imaging Features
Penetrating injury

A bed sore with osteomyelitis

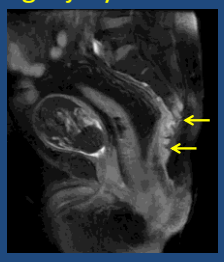

Imaging Features
Cellulitis

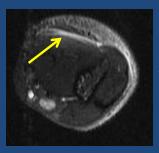

Axial Arm STIR

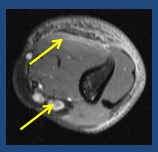

T1+Gd

- Subcutaneous tissue infection
- Edema and enhancement of the subcutaneous tissue and superficial fascia

Imaging Findings
Cellulitis

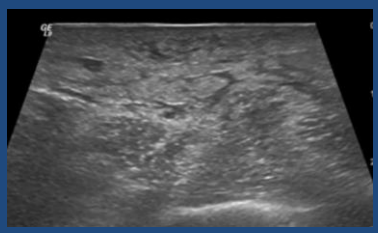

Transverse scan of the left mid thigh
Thickened subcutaneous tissue and interlobular septal fat

Imaging Features
cellulitis & superficial soft tissue abscess

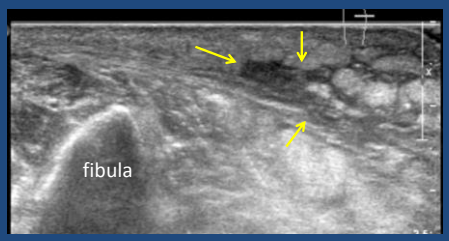

Transverse scan of the calf

Imaging Features
cellulitis & superficial soft tissue abscess

- A 42 yo woman with HIV infection and S. epidermidis soft tissue abscess

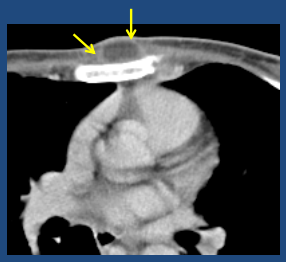

Imaging Features
Necrotizing Fasciitis

Necrotizing Fasciitis with skin necrosis

Imaging Findings Necrotizing Fasciitis

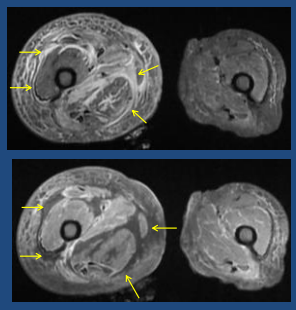

- Thickened T2-hyperintense
- Non-enhancing fascia

STIR

T1+Gd

Imaging Features Necrotizing Fasciitis

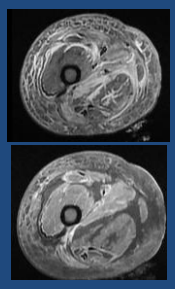

Necrotizing vs non-necrotizing fasciitis

- Presence of gas
- Significant thickening of the abnormal signal intensity of the fascia on T2-weighted images (> 3 mm)
- Non-enhancing fascia
- Multiple compartment

Kim KT, Radiology 2011, 259 :816-24

Imaging Features Pyomyositis

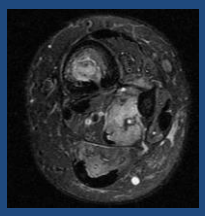

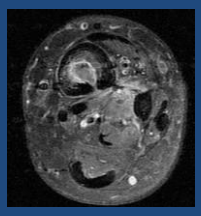

Early stage

- Hyperintense signal on T2WIs
- Muscle enhancement

Imaging Features Pyomyositis

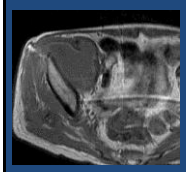

T1WI

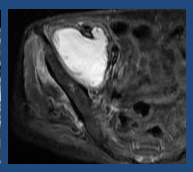

T2WI with fat suppression

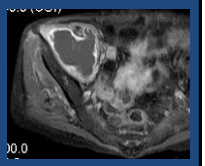

T1WI +Gd

Pyomysitis

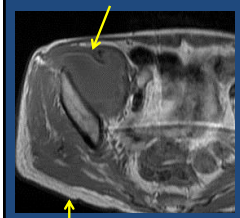

Bleeding
Iron in bacteria or macrophage
Free radical

T1WI

Bleeding
Fibrosis

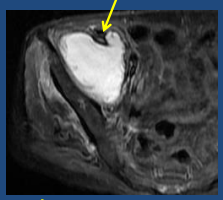

T2WI with fat suppression

Pyomyositis: Abscess wall

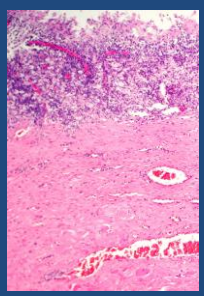

Inflammatory cells

Fibrosis+Inflammatory cells + blood vessels

H&E

Imaging Features Osteomyelitis

Stages : no-clear distinction

- Acute osteomyelitis
- Subacute osteomyelitis > 2-3 Weeks
- Chronic osteomyelitis >3 months

Bone destruction → Abscess formation → Reactive bone formation

Tissue necrosis
- bone
- bone marrow

Imaging Features Osteomyelitis

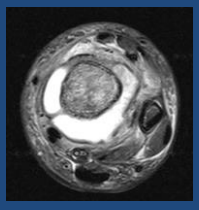

4-year-old boy
Axial T2WIs with fat saturation

Imaging Features Osteomyelitis

- Moth-eaten osteolytic lesion in the metaphysis with cortical destruction and laminated periosteal reaction

DDx 1. Osteomyelitis
2. Ewing sarcoma
3. Other small round cell tumors : lymphoma leukemia

Imaging Features Osteomyelitis

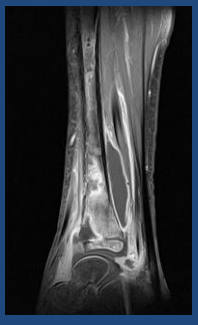

- Extensive bone marrow edema
- Subperiosteal abscess
- Formation of abscesses is the hallmark of infection

Sagittal T1+Gd

Imaging Features Osteomyelitis

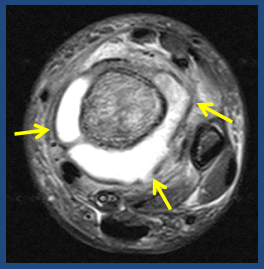

Periosteum in children is loosely attached to the bone

↓

Extensive subperiosteal reaction & Infarction of bone

↓

Involucrum & sequestrum

Imaging Features Osteomyelitis

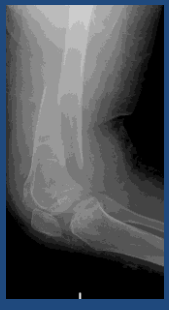

- Acute osteomyelitis in adult
- A 31-year- old woman with pathologic fracture of the distal femur

Acute osteomyelitis in adult

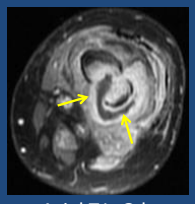

Axial T1+Gd

Abscess

Imaging Features Osteomyelitis

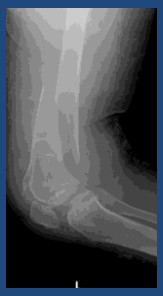

Periosteum in adult is firmly attached to the bone

↓

Increased intraosseous pressure

↓

Fracture

Imaging Features Osteomyelitis

- Brodie's abscess

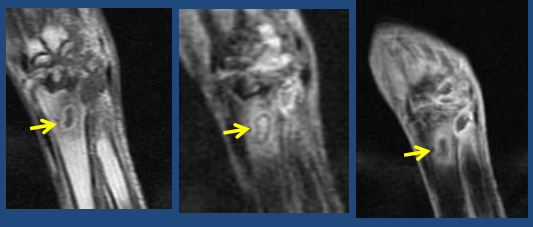

T1WI T2WI T1+Gd

A 44- year-old woman

Tuberculous osteomyelitis/arthritis

Coronal MRI of the wrist

T1-weighted image

Tuberculous arthritis & osteomyelitis

- " penumbra zone" T1-hyperintense rim due to fibrovascular tissue with hemorrhage
- Sensitivity 73.3%*
  Specificity 99.1%

* Shimose S. Acta Radiologica, 2008

MRI Features of Osteomyelitis

Brodie's abscess

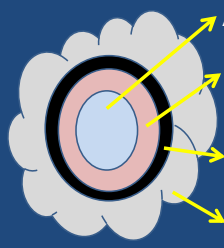

Vascular channels & Osteomyelitis

Neonate-18 mo 18 mo-16 yrs >16 yrs

Infection begins in medullary cavity of metaphysis or near the physis of flat bones.

Vascular channels & Osteomyelitis

- Transphyseal spread/transphyseal tunneling

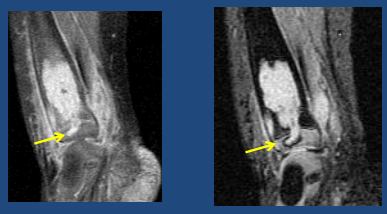

T1WI GRE

A 10 month-old girl with osteomyelitis of the distal tibia

Osteomyelitis

Axial view of the foot

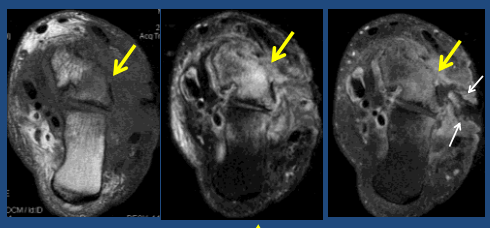

T1 signal intensity ↓ T2 signal intensity ↑ Enhanced on post contrast study

: A 52 yo M, DM & ulcer lateral malleolus

Osteomyelitis

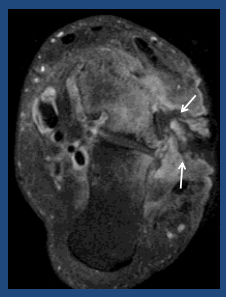

Osteomyelitis in the diabetic foot is almost always associated with skin ulcer or soft tissue infection

Commonly associated with bone prominences: metatarsal head, calcaneus, malleoli, and toes.

Role of Imaging in Septic Arthritis

- Diagnosis made by presence of painful joint, fever, purulent synovial fluid
- Helpful in the diagnosis if synovial fluid cannot be obtained
- Distinguish septic arthritis from contiguous infection (most common- osteomyelitis)

Imaging Features Septic arthritis

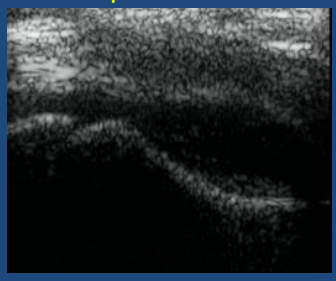

A 4 yo girl with septic arthritis of the right hip

Imaging Features
Septic arthritis

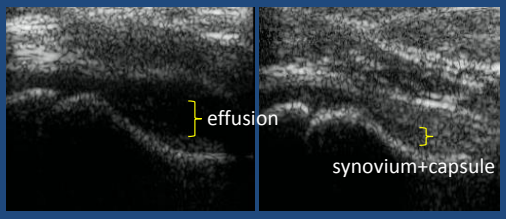

A 4 yo girl with septic arthritis of the right hip

Imaging Features
Septic arthritis

Gouty arthritis

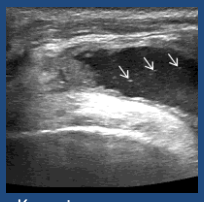

Knee transverse scan

Septic arthritis of the ankle 33/M

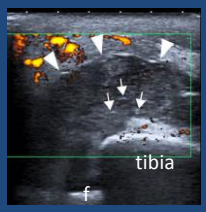

Ankle transverse scan

Imaging Features
Septic arthritis

57/M septic arthritis

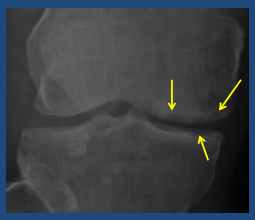

23/F Regional osteoporosis

Imaging Features
Septic arthritis

Findings

- Joint effusion
- Synovial hypertrophy & enhancement
- Bone marrow edema
- Bone erosions

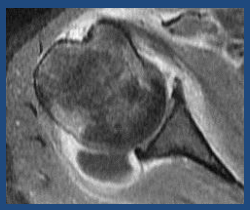

MRI of infected and noninfected joints

	Infected (%)	Non-infected(%)
-Joint effusion	79	82
-Inhomogeneous effusion	21	27
-Synovial thickening	68	55
- Synovial enhancement	94	88
- Bone erosion	79	38
- Bone edema	74	38

Graif M. Skeletal Radiolo 1999

Complication of Septic Arthritis

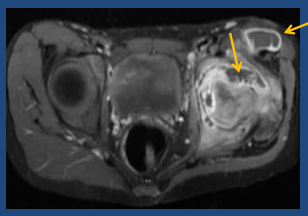

Erosions and bone edema

Paraarticular abscesses

(indicate disruption of joint capsule)

Complication of Septic Arthritis

- Tenosynovitis

Synovial hypertrophy& enhancement

Tendon sheath effusion

Tendon rupture

Axial T1+Gd of the hand

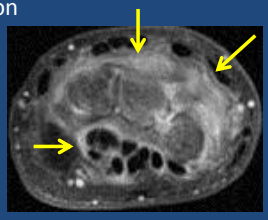

Complication of Septic Arthritis

- Tenosynovitis

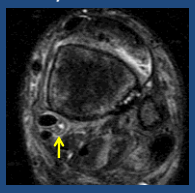

T2WI with fat sat

T1WI+Gd

Complication of Septic Arthritis

- Synovial hypertrophy& enhancement
- Tendon sheath effusion
- Tendon rupture

Sagittal T1+Gd of the ankle

Conclusion

Roles of imaging studies are

- Detection of infection
- Define the extension (superficial/deep infection)

Imaging patterns of extremity infection are the results of

- Source of infection : hematogeneous spread, contiguous sources, penetrating injuries
- Affected compartments
- Tissue destruction, abscess formation
- Tissue responses